


AGD 2016 BOSTON
REVOLUTIONARY CHANGES IN DENTISTRY



**Case Review:
Combined Office and OR General Dentistry**

Harvey Levy, DMD, MAGD, LLSR
July 14, 2016

Our practice: Who We Are



www.DrHLevyAssoc.com

**Our
Office
Staff**



My goal is to be a...



**As a general dentist,
you are limited only by:**

Your Confidence



**and your
competence.**



Case Review: Huntington's Disease

Harvey Levy, DMD, MAGD, LLSR

ACADEMY OF GENERAL DENTISTRY
JULY 14, 2016

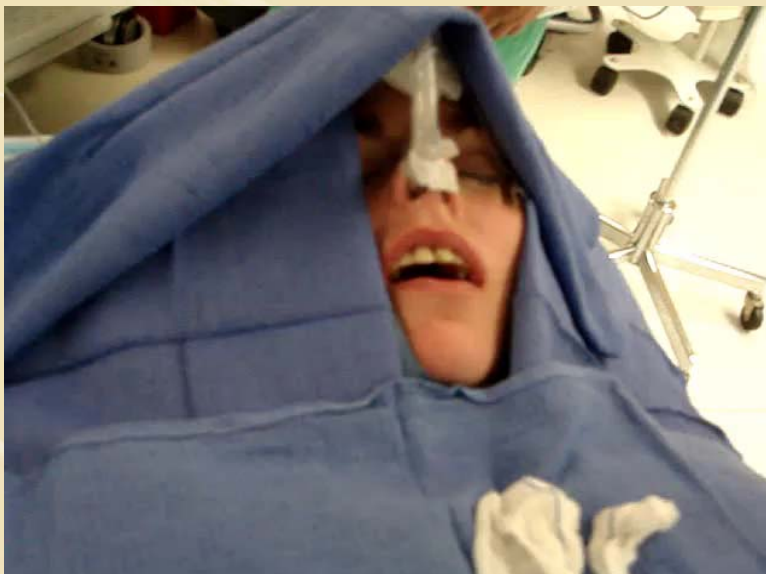

Huntington's Disease in the Office and...

Loretta D.,
age 40



Huntington's Disease in the O.R.



Huntington's Disease

- Was called Huntington's Chorea
- Chorea means **"dance"**
- Inherited, progressive, degenerative brain disorder
- Produces physical, mental, emotional changes with dementia and psychiatric problems

Huntington's Disease

- Described by **American physician** George Huntington (1872)
- **Single faulty gene** on chromosome #4 (1993)
- Autosomal dominant (**50% pass to child**)
- One in 30,000 in U.S.
- No race or gender bias

Huntington's Disease

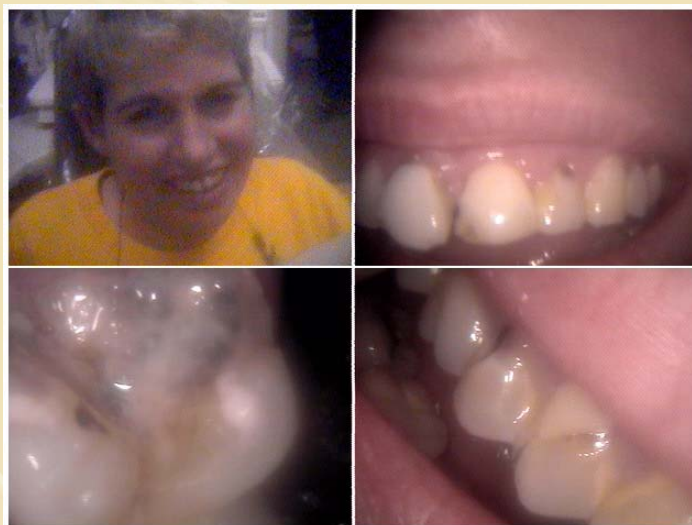- Typical onset age **35-50**
- **Typically fatal** w/n 15-20 years p onset s/s
- Fatalities usually caused by
 1. Infection
 2. Suicide
- **Woody Guthrie (1912-67)**



Dental Physical Symptoms

- Grind and clench teeth
- Unable to open mouth wide
- Dysphagia (difficulty swallowing)
- Dyslalia (severe darting movement of tongue and head)
- Facial muscle movements eject dentures
- Cannot sit still

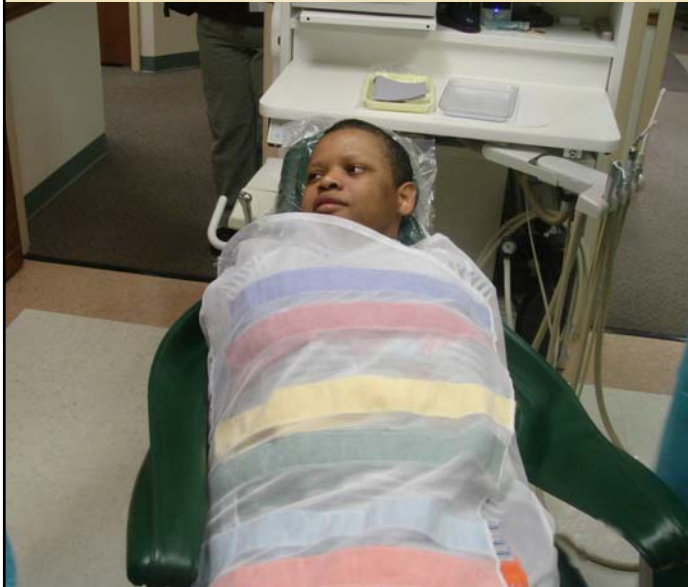Pre-op Intraoral camera



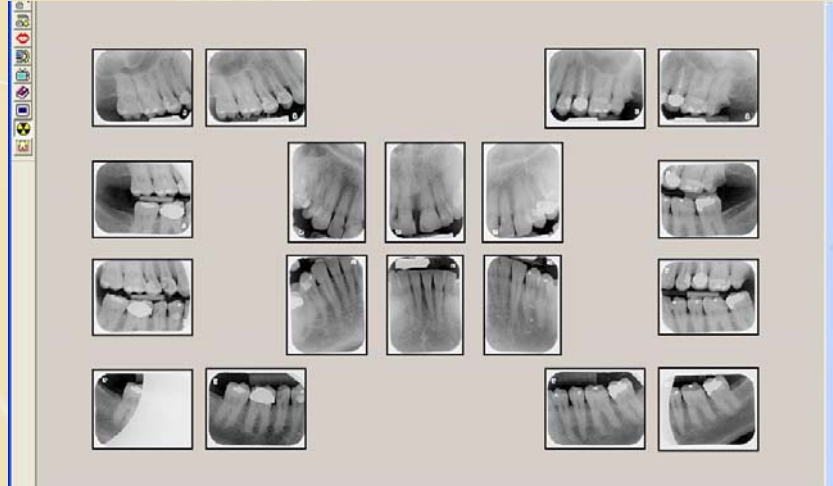
Six sizes of Rainbow wraps



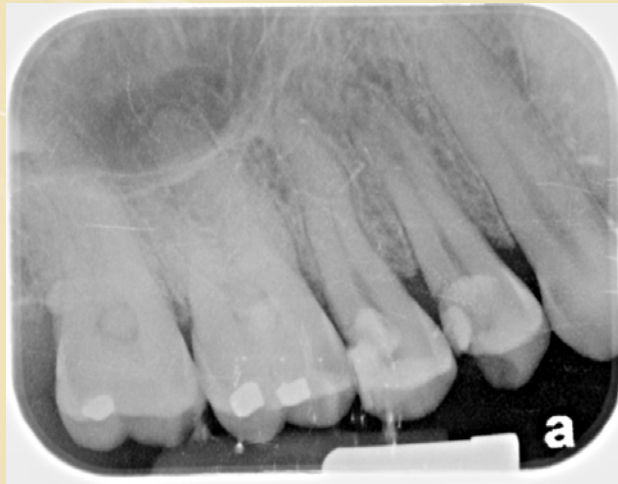Wraps (different patient)



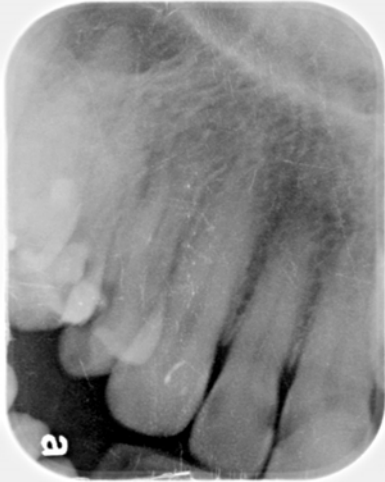Full series Loretta D.



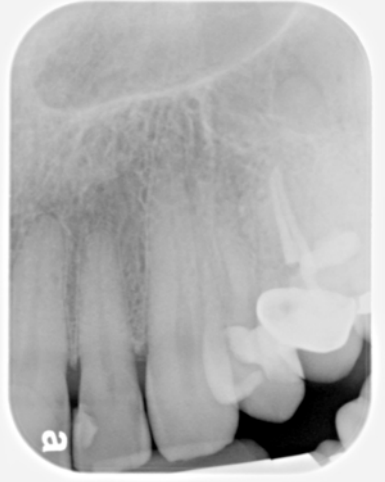Teeth #3, 4, 5



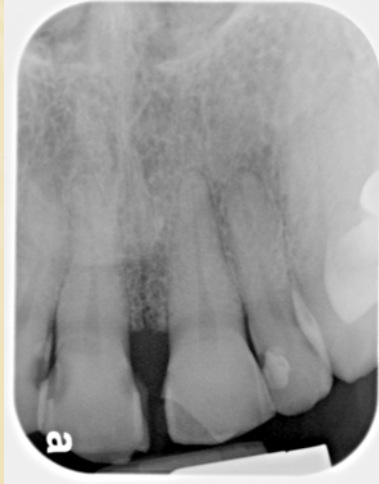Teeth #7, 8



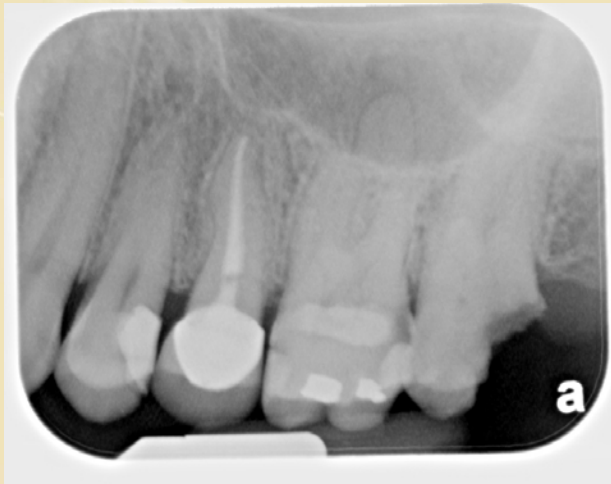Teeth #9, 10



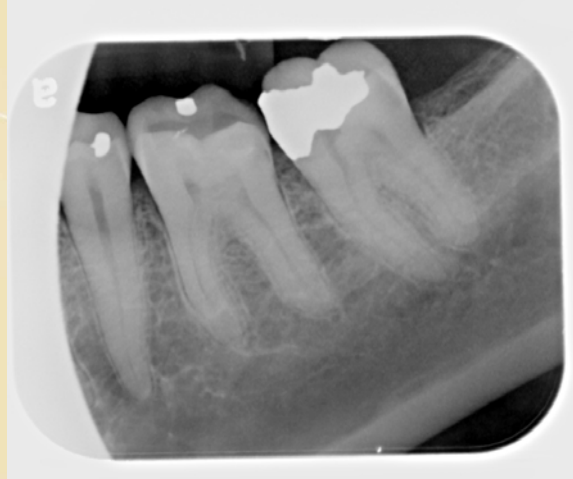Teeth #7, 8, 9, 10



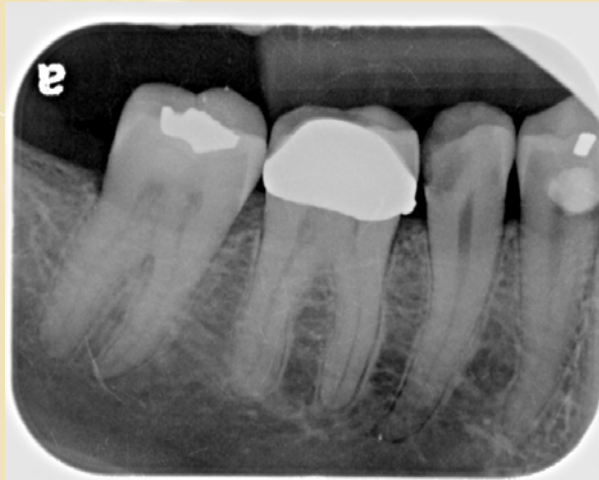Teeth #12, 14, 15



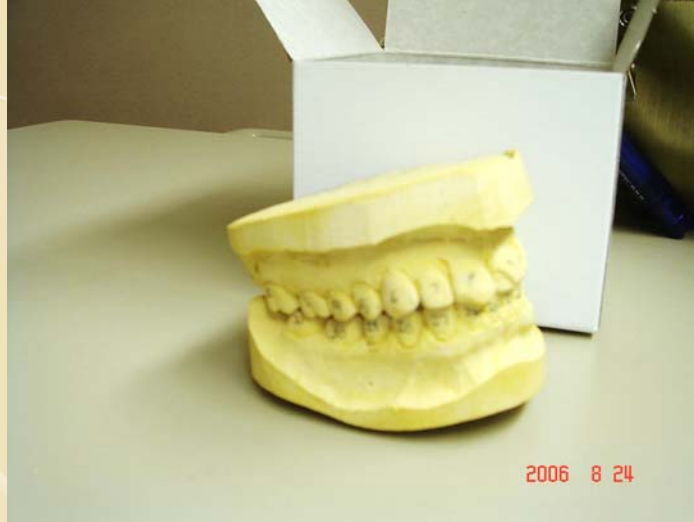Teeth #18, 19



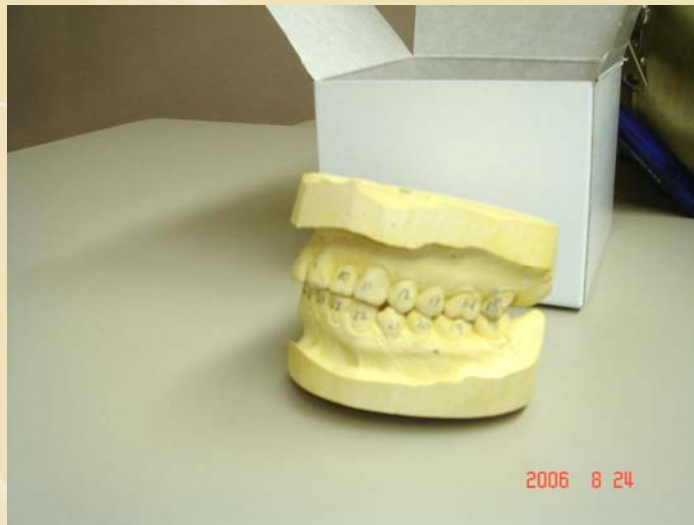
Tooth #29



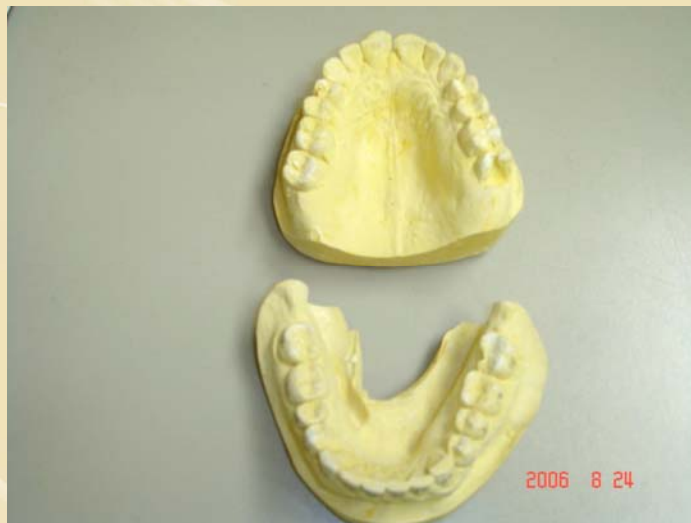Tooth #29



Pre-op models: left side



Fractured & abscessed #15, 18



Loretta D (1st visit)

- Xerostomia (dry mouth)
- Multiple dental caries
- Abscessed and fractured teeth
- Gingivitis
- Frequent involuntary head/body movements
- Reduced manual dexterity

Treatment in OR

Multi-disciplinary dentistry:

- Crowns
- Restorations
- Extractions
- Possible root canal
- Prophylaxis
- Fluoride

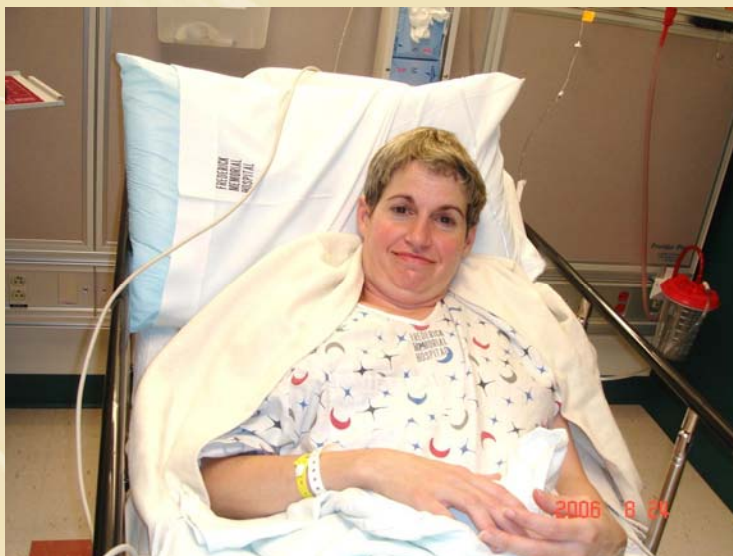2-day follow-up

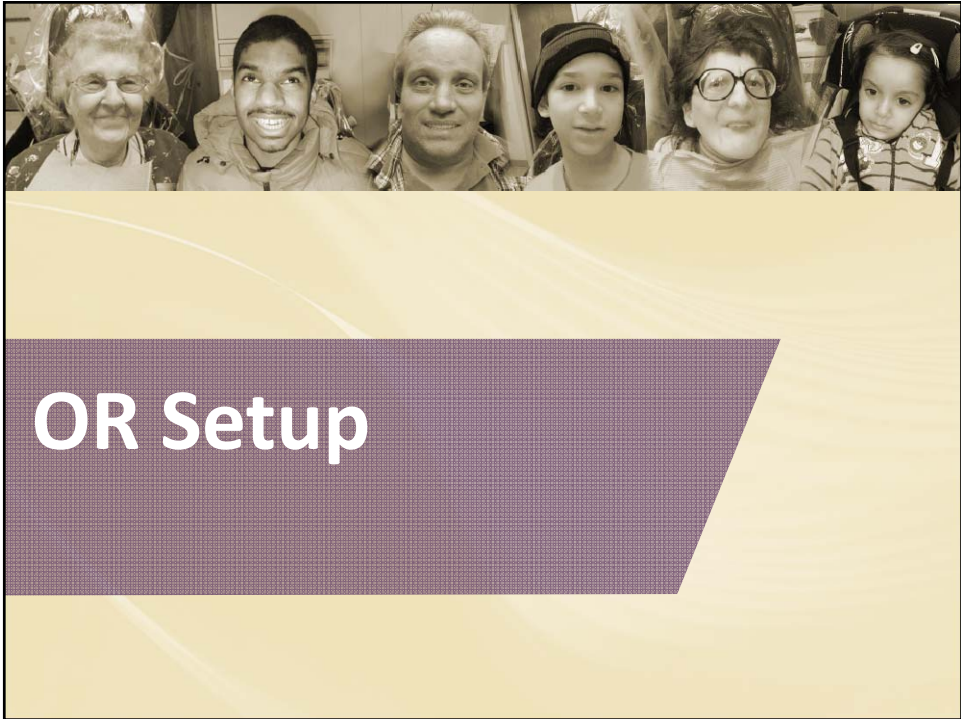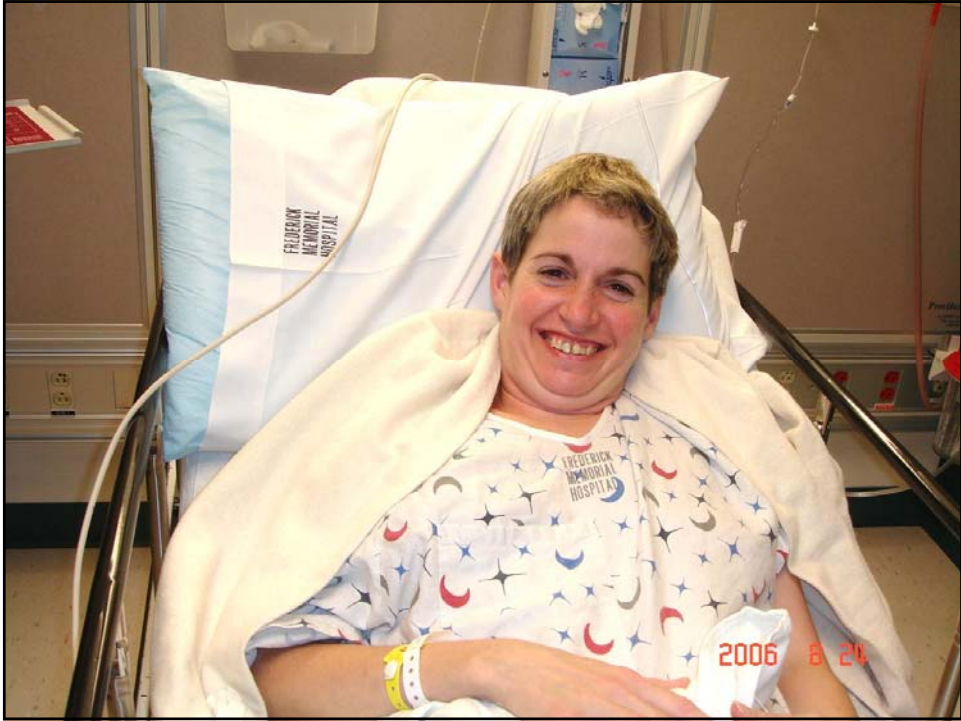- Smooth temporary crowns
- Check restorations
- Check extraction sockets

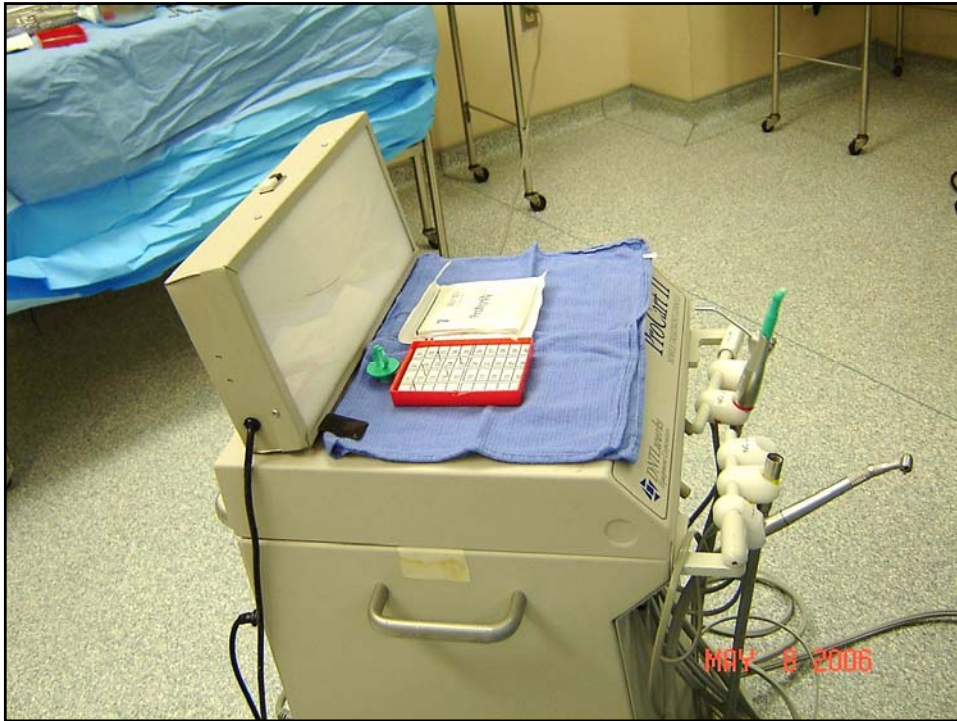2-week follow-up

- Cement crowns
- Check sockets, restorations
- Discuss oral hygiene modifications due to impaired manual dexterity and xerostomia

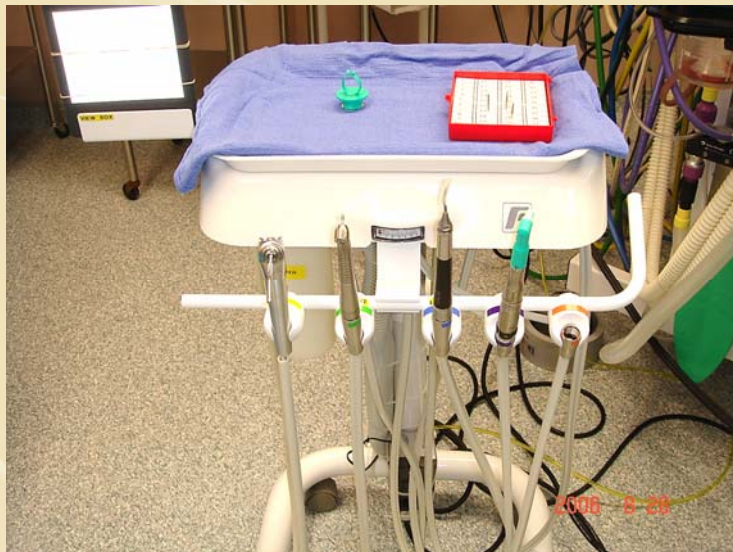Loretta in pre-op



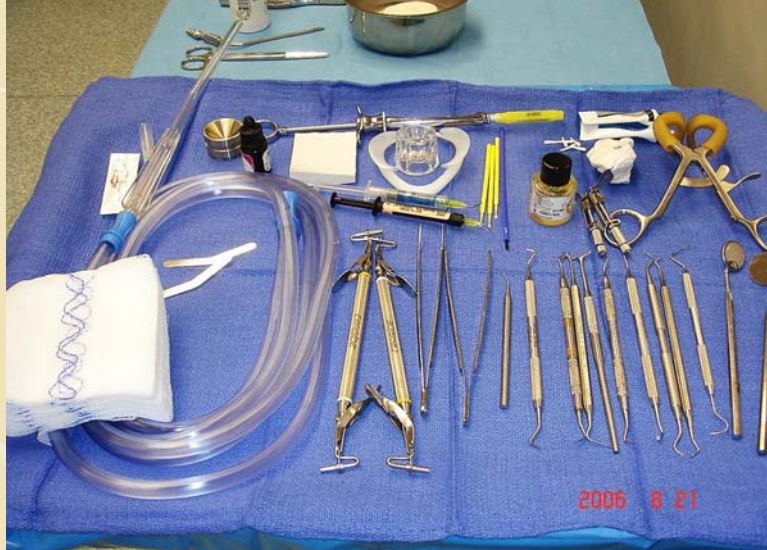



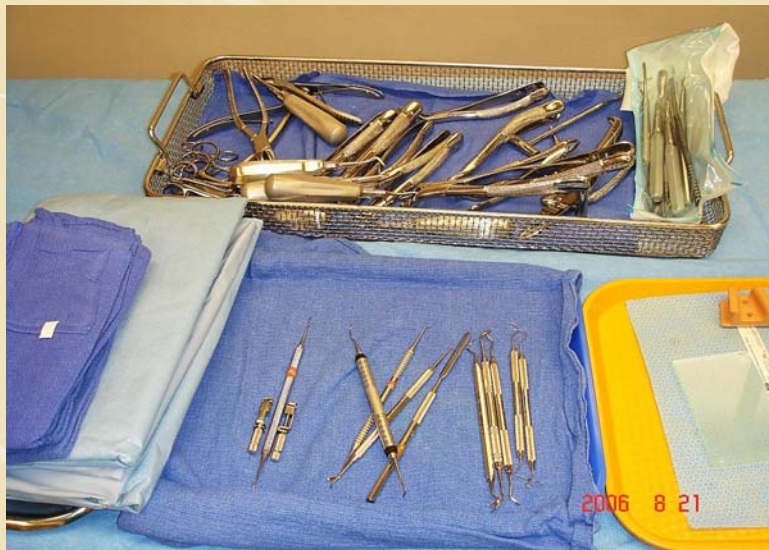Back-up cart in OR



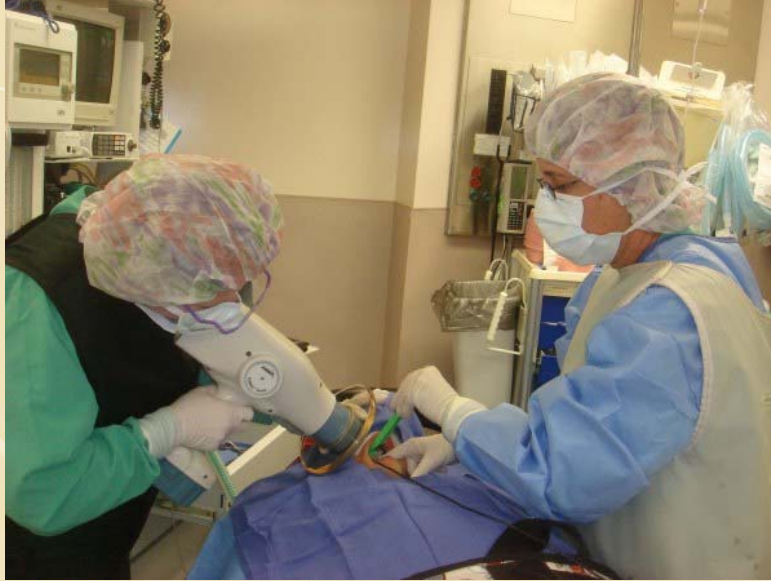OR restorative setup



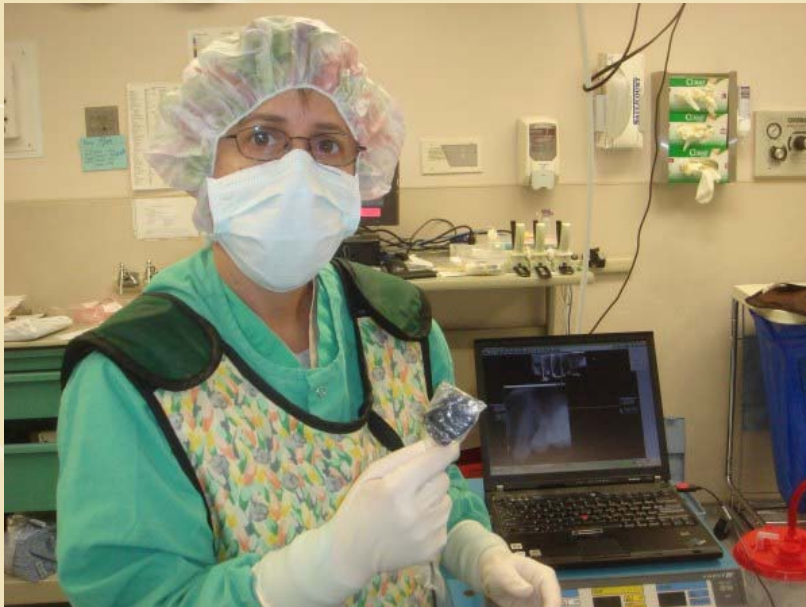Restorative and extractions



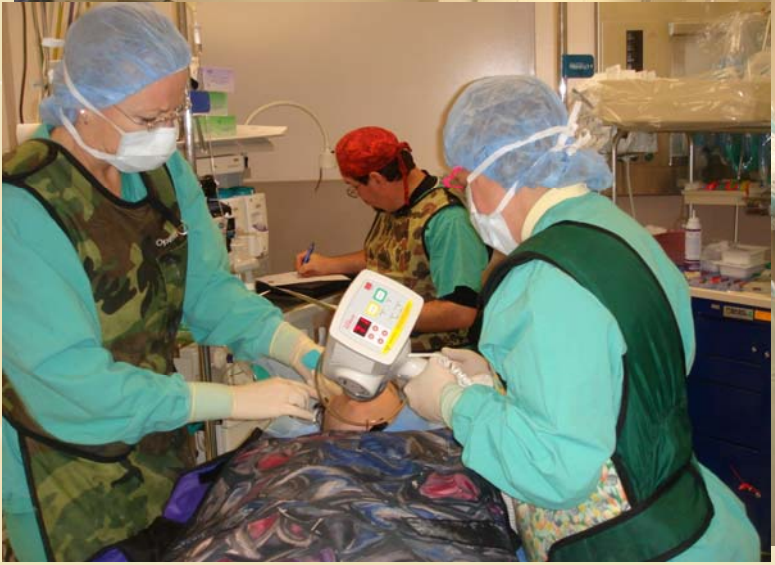X-ray expose and process



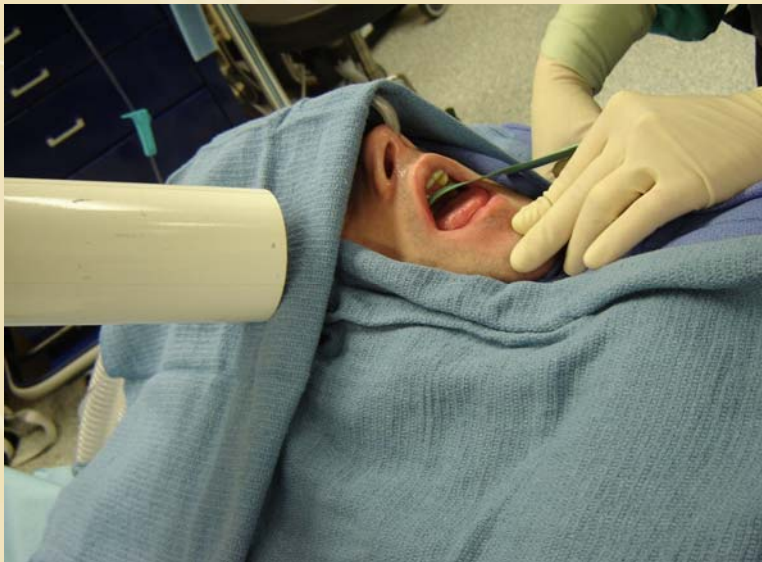X-ray expose and process



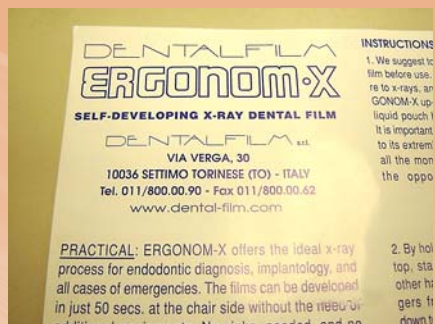X-ray expose and process



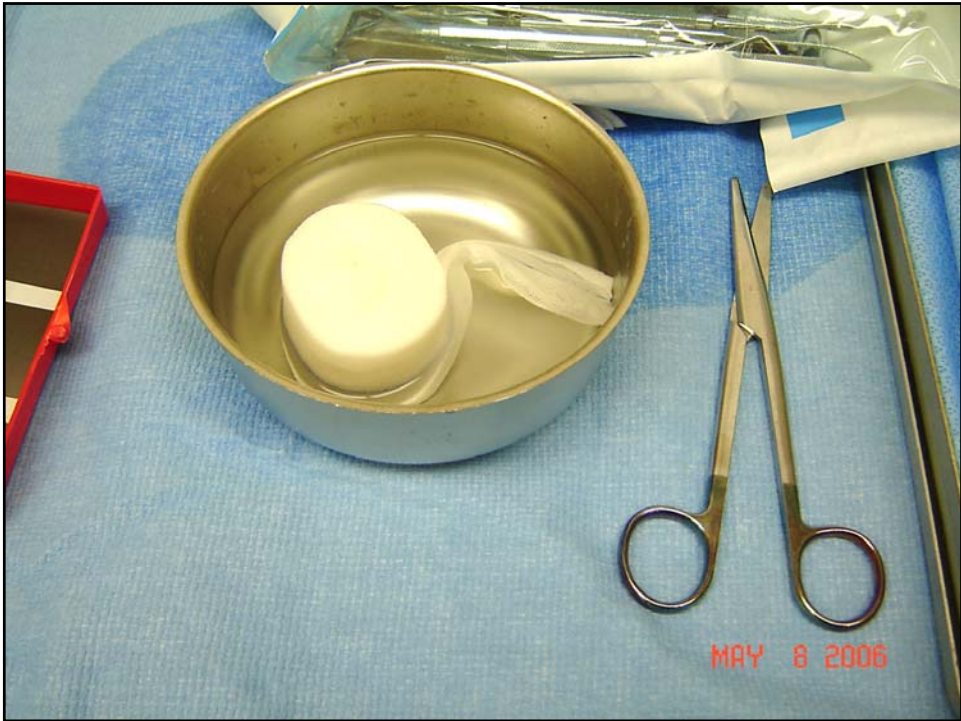X-ray expose and process



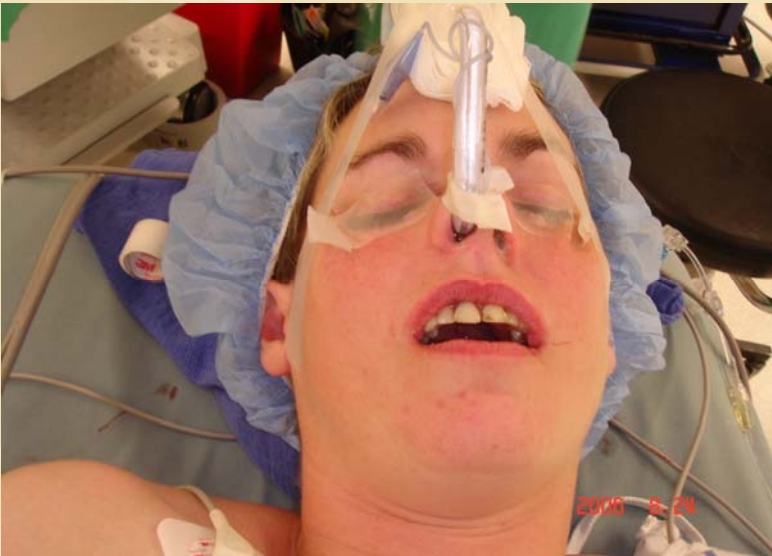Ergonom-X: Self-developing film



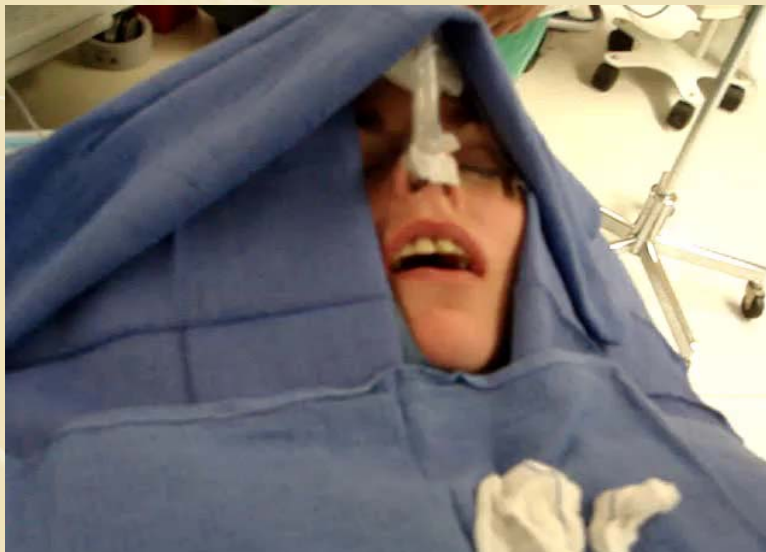Throat pack



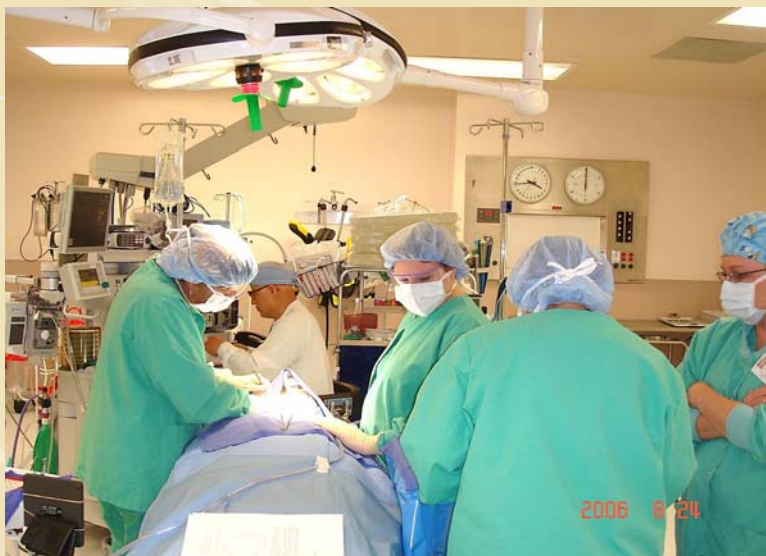Nasal intubation in OR



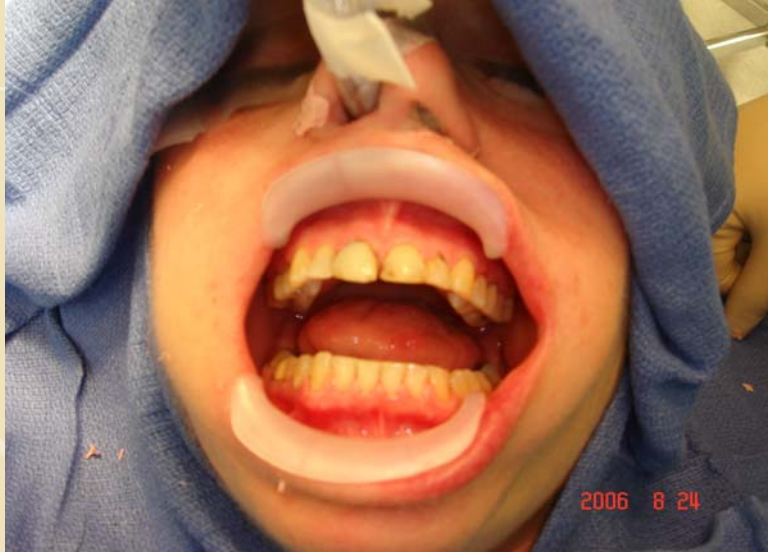Throat pack inserted



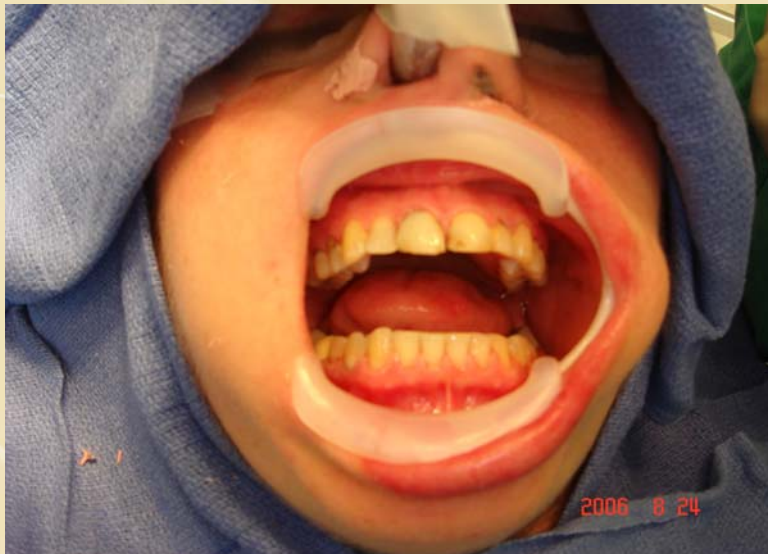Review prelim exam



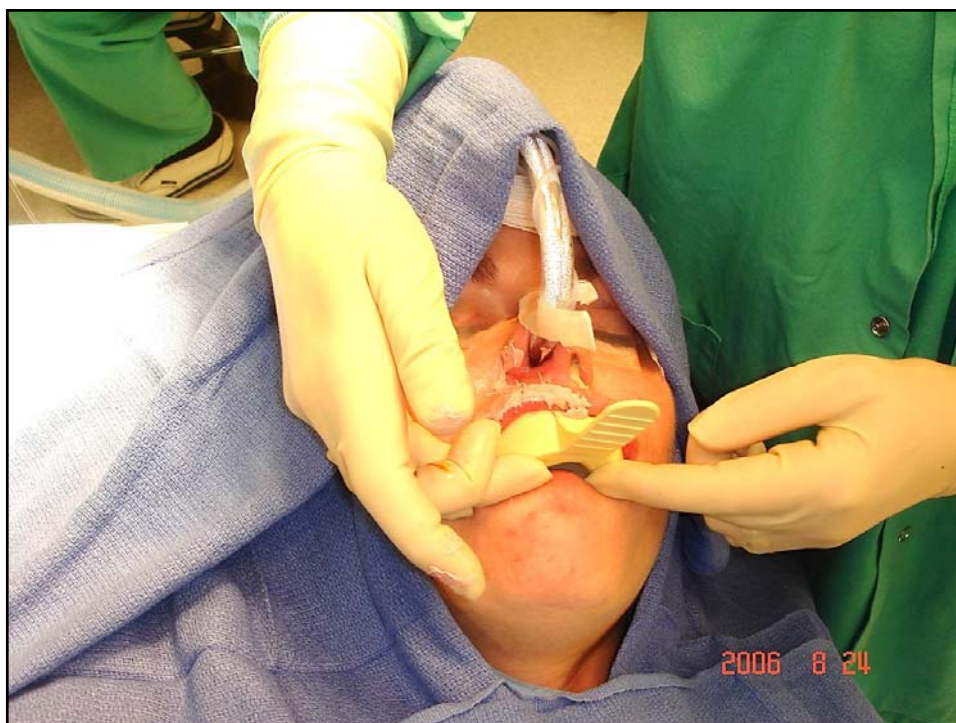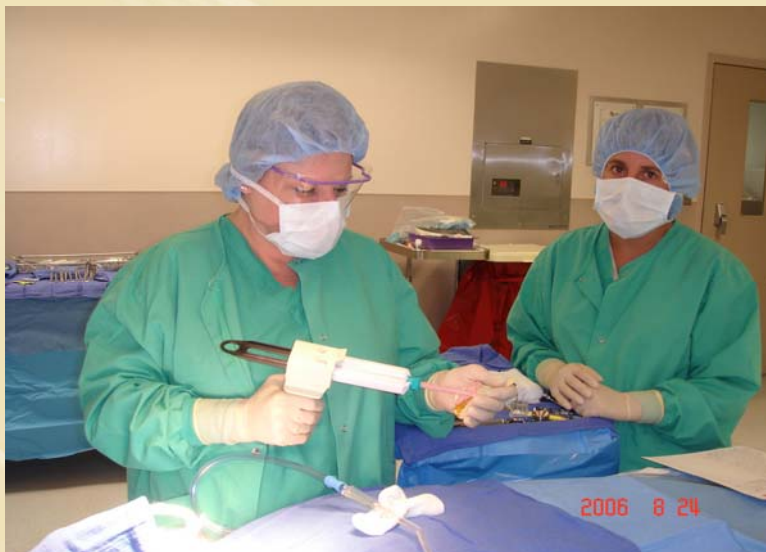Pre-op for crowns #7-10



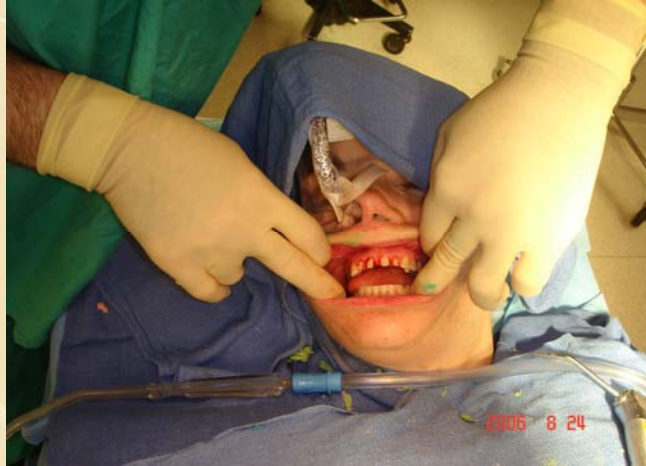Pre-op for crowns #4, 5, 29



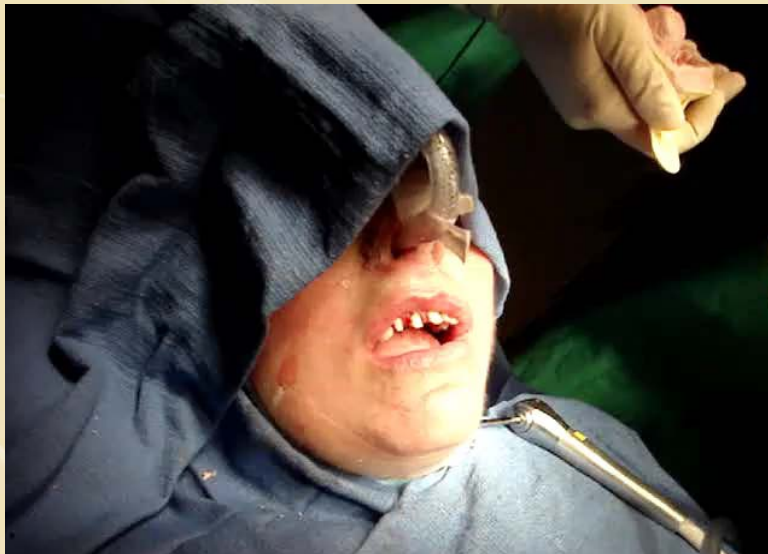2 assistants make temporary crowns



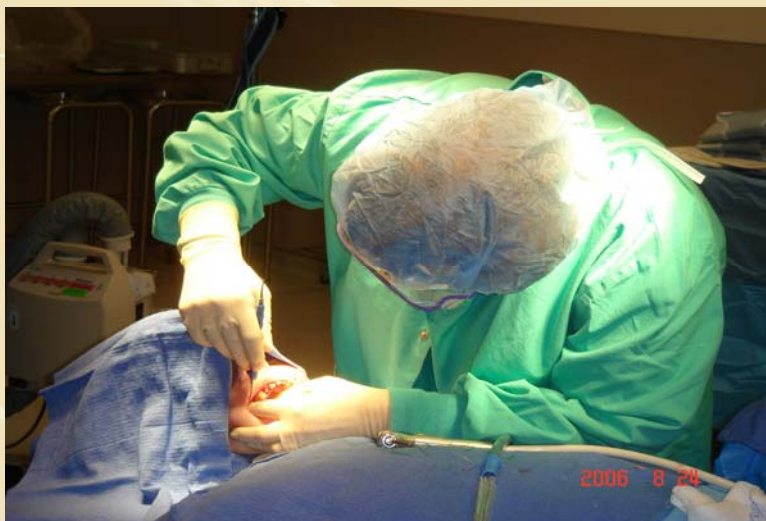Restorations, prep crowns 4,5,7-10,29



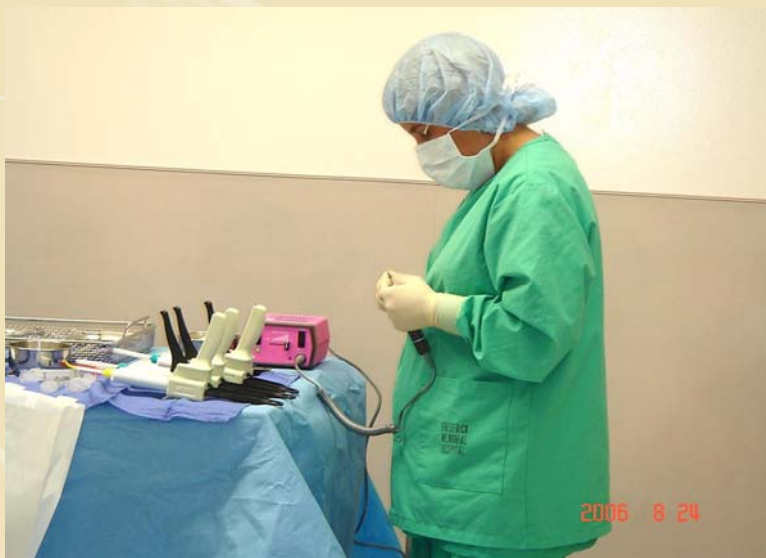Making temporary crowns



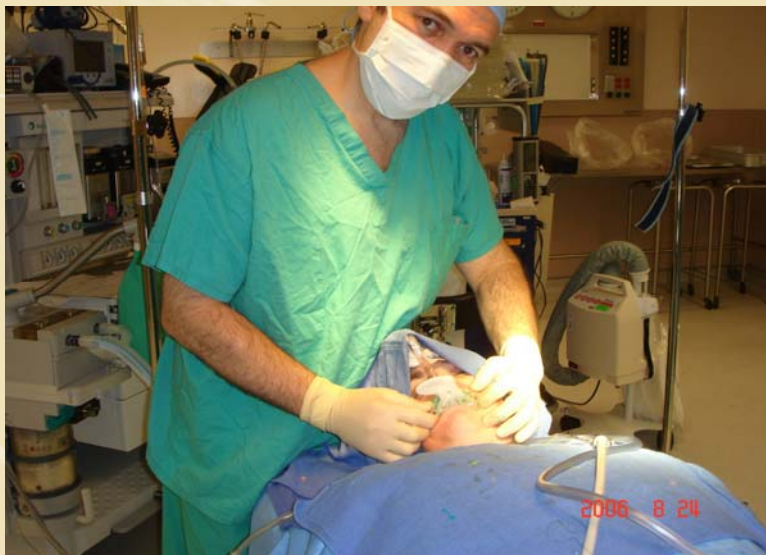1st assistant packs cord for 7 crown impressions



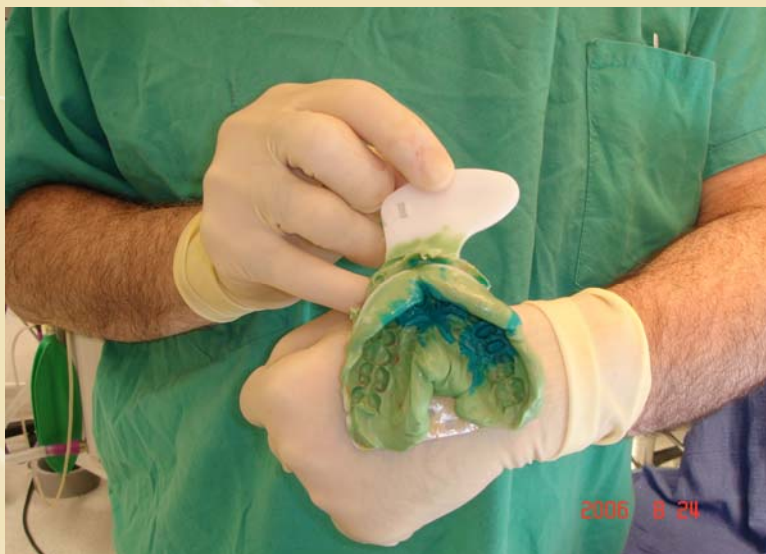2nd assistant works on 7 temporaries



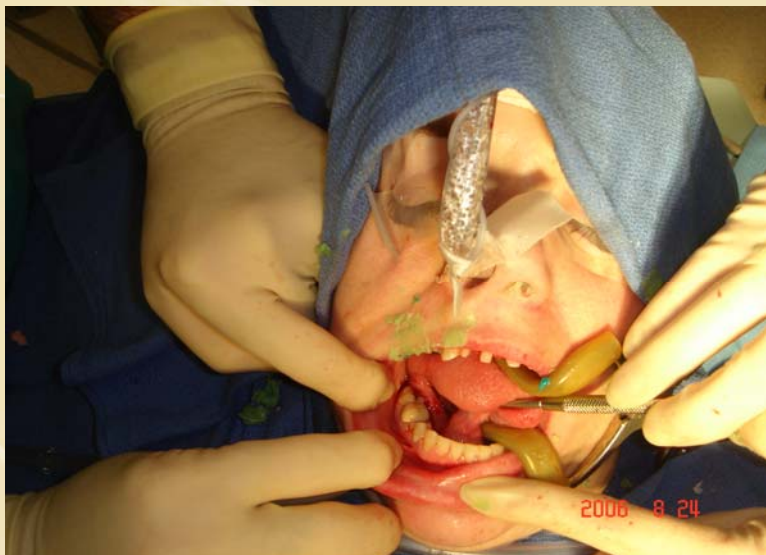Holding crown impression tray



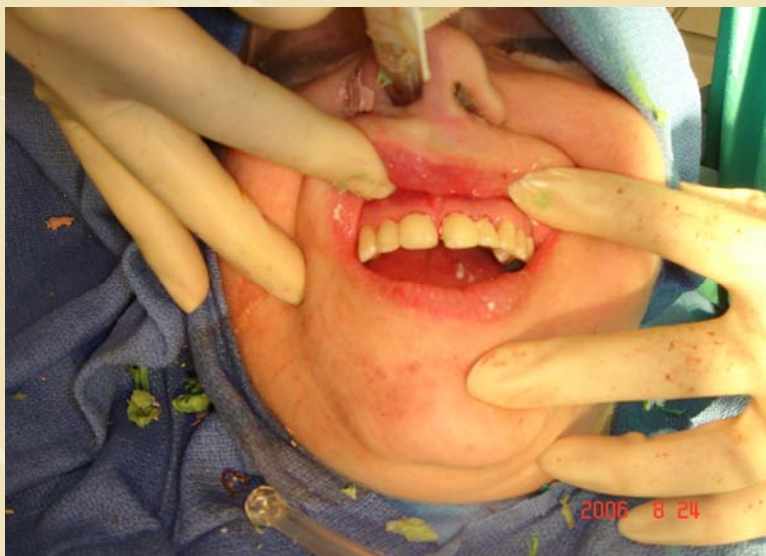Impression for crowns 4, 5, 7-10



Placing 7 temporaries



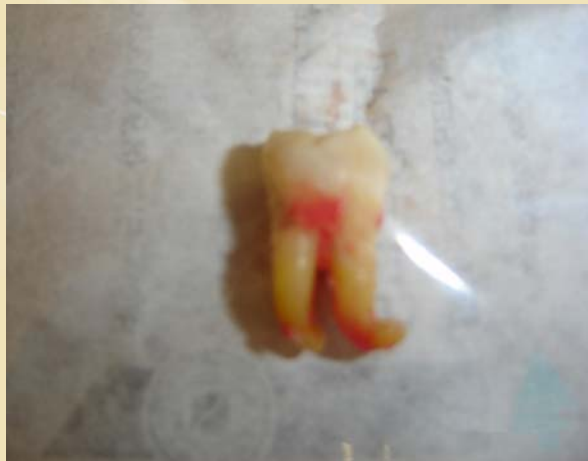Temporaries cemented





Extractions

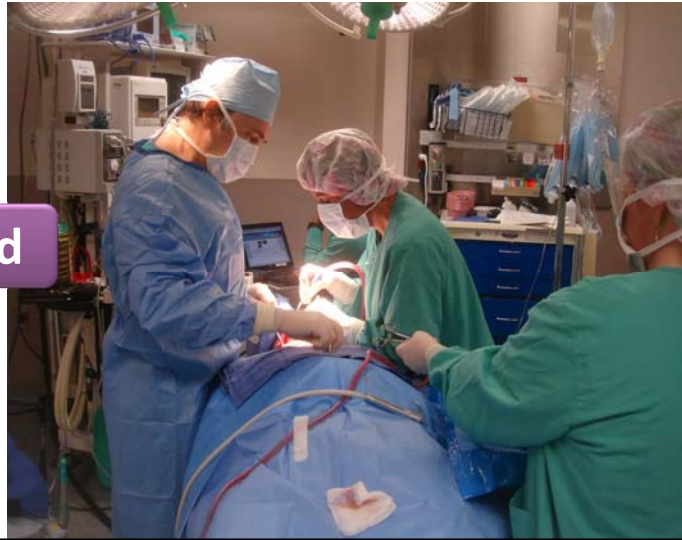Extractions are last!



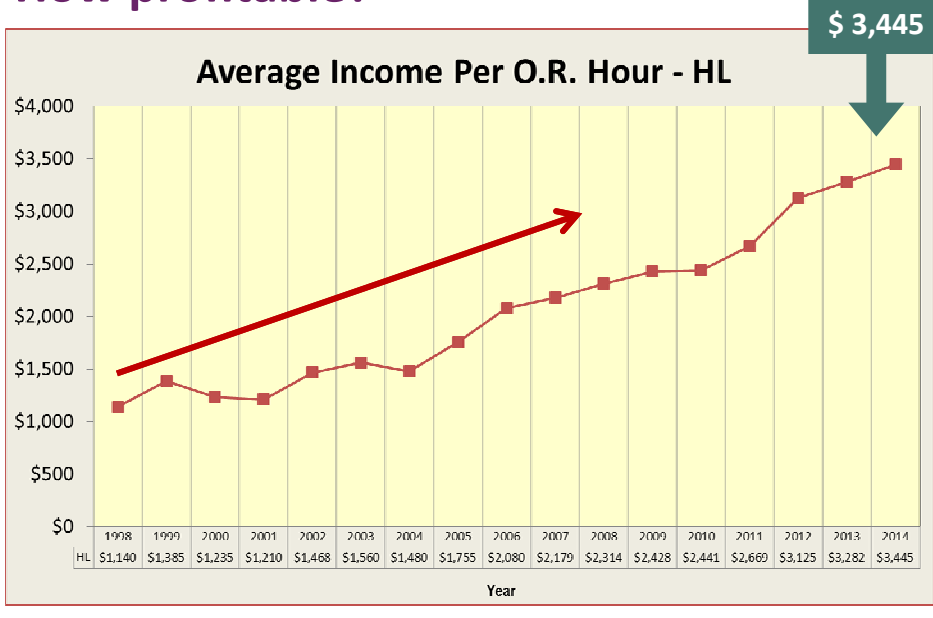
Extracted teeth #15, 18

O.R. promotes quadruple efficiency

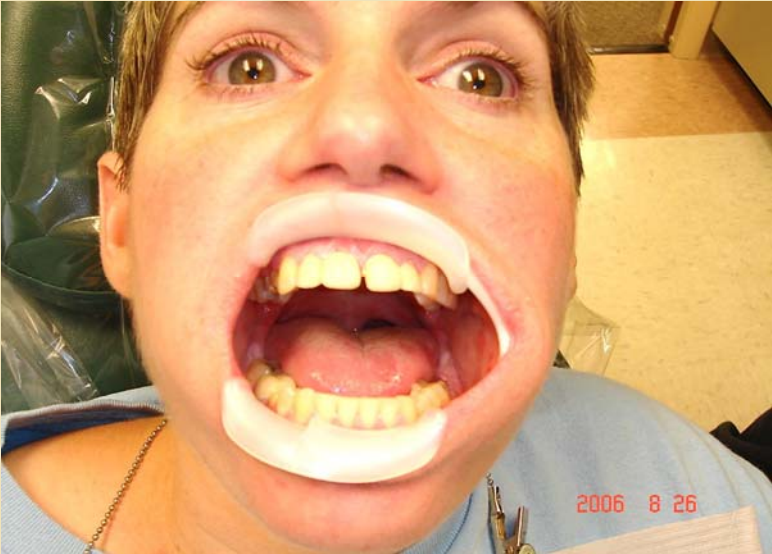Six-handed



How profitable?



Follow-up 2 days post-op



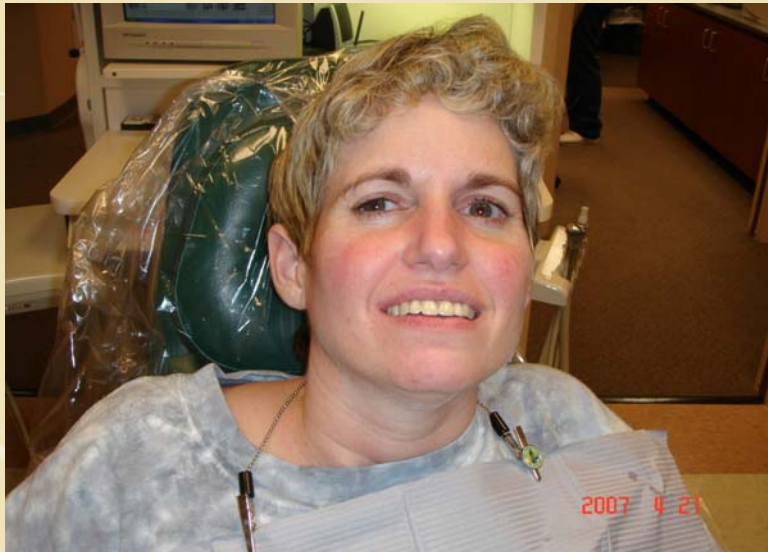Crowns cemented after 2 weeks

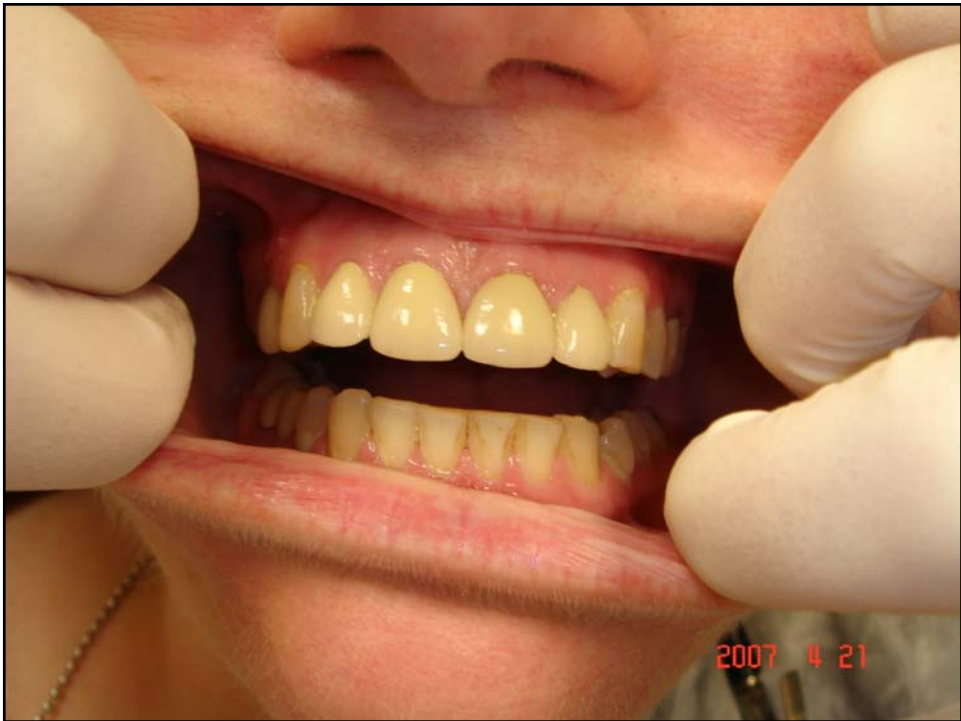
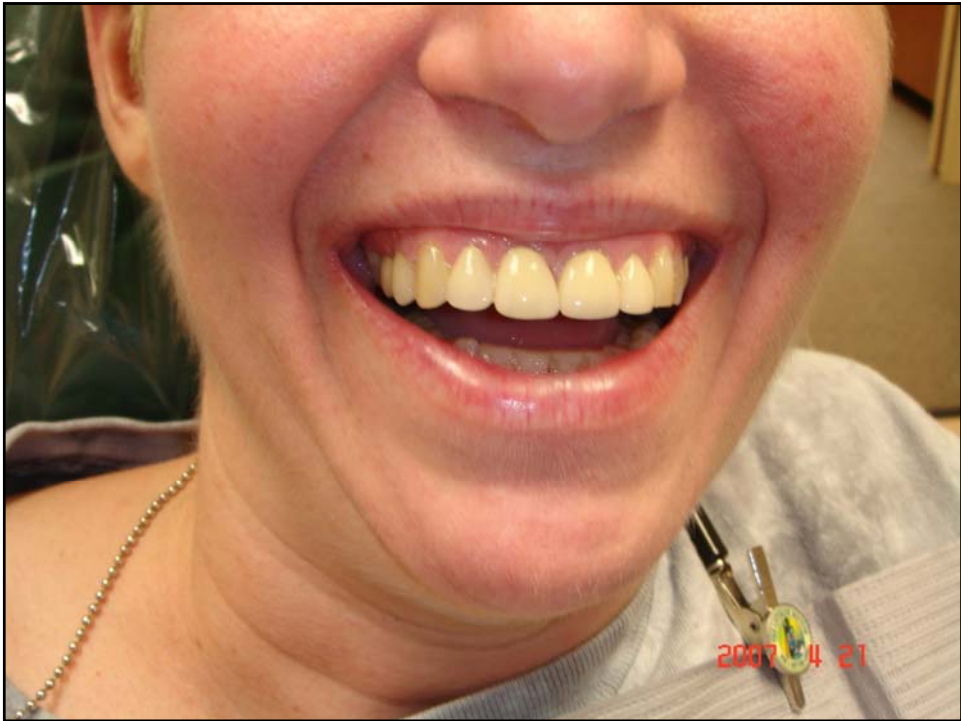
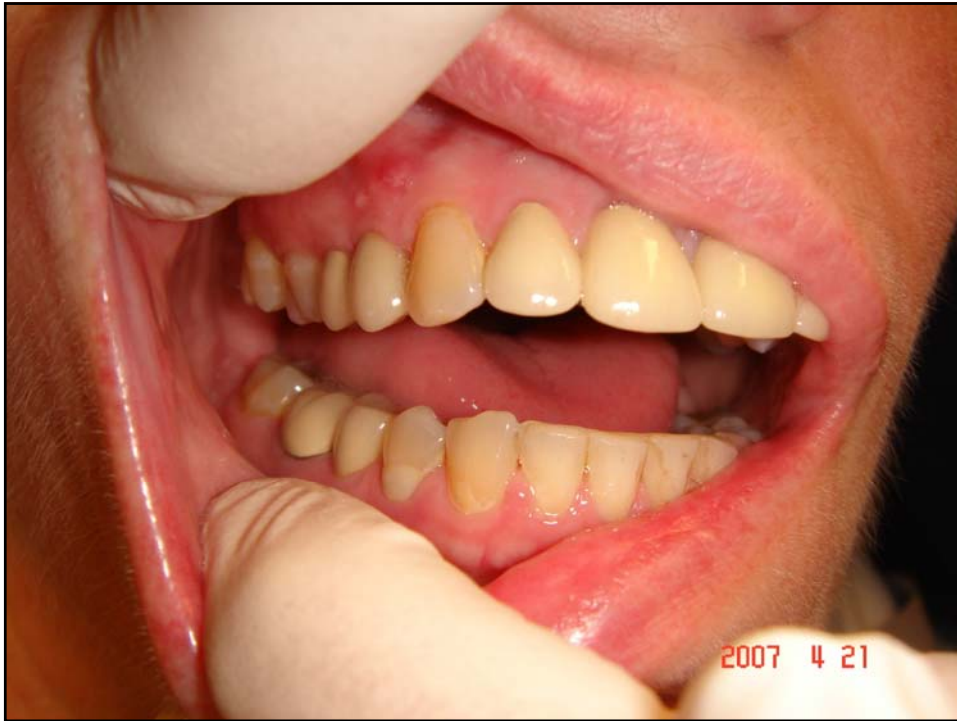Recall follow-up, 8 months later



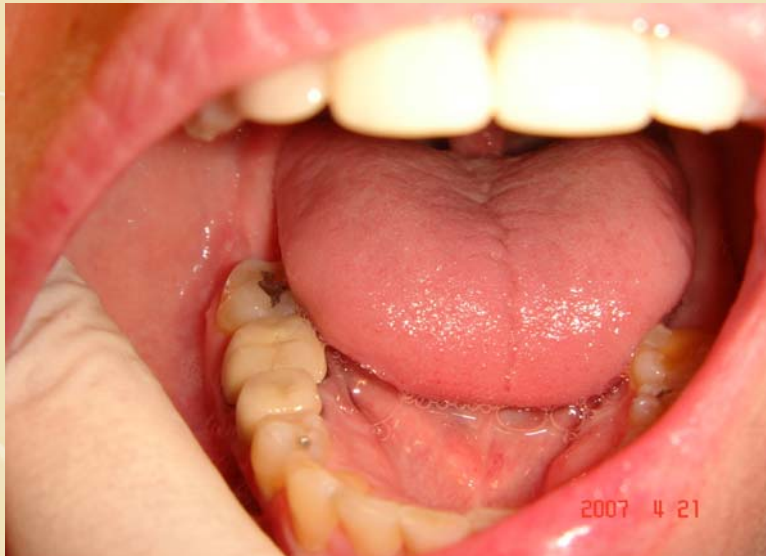Before cleaning



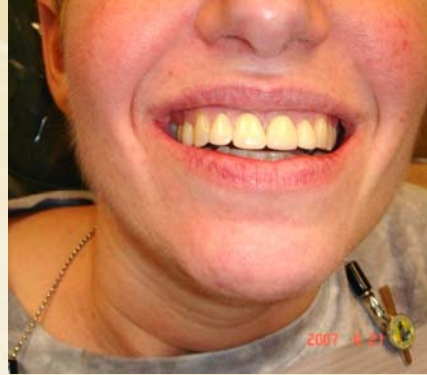
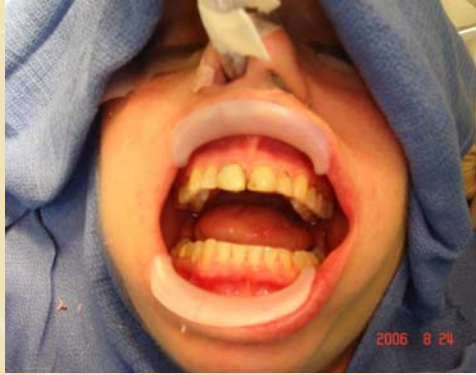


First recall after 8 months



Before and After



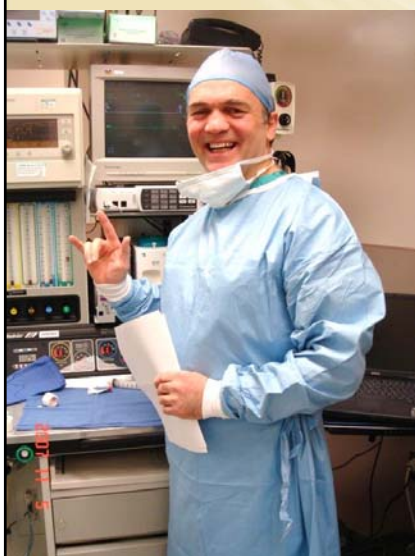**What is your take-home
'pearl' from this?**



Opportunity: Don't miss the boat



Harvey Levy, DMD, MAGD



Dr. Harvey Levy
198 Thomas Johnson Dr
Ste 108
Frederick, MD 21702
301-663-8300
drhlevy@gmail.com
DrHLevyAssoc.com