A CASE OF HYPERTENSION AND ACUTE RENAL FAILURE

Maricel Pilapil-Pureza
WLA Nephrology

OBJECTIVES

After the presentation, the attendee will be able to:

1. Discuss when to suspect for secondary causes of Hypertension
2. Discuss appropriate work-up of secondary hypertension based on clinical setting

CASE PRESENTATION

32 y/o hispanic female

REASON FOR REFERRAL

elevated creatinine

HISTORY

-HTN diagnosed in her 20's, no regular follow up
-presented with uncontrolled HTN and headaches
-lean, non diabetic
-no NSAIDs, no herbals

REVIEW OF SYSTEM:

- Intermittent generalized headaches
- No syncope nor diaphoresis
- No tinnitus, No visual loss
- No neck pain
- No chest pains nor palpitations
- No SOB
- No abdominal pain
- No flank pain nor hematuria
- + intermittent pain on legs

PMHX:

- HTN

FHX:

- no HTN
- No ESRD

SOCIAL:

- Non smoker
- Non drinker
- No illicit drug use

MEDICATIONS:

Ferrous sulfate

Lisinopril-HCTZ 20-12.5 mg bid

PHYSICAL EXAM:

- BP: 129/67 mm HG (similar in both arms) 65/min
- BMI: 21, normal stature
- GEN - Alert and Oriented, in No Acute Distress
- HEENT- pink palpebral conjunctivae, no papilledema
- no carotid bruit
- CVP: 7cm
- CHEST - Clear to Auscultation Bilaterally, No Wheezing, Rales or Rhonchi
- CV - Regular Rate and Rhythm, Without Murmur
- ABD - Soft, non tender, no abdominal bruit
- EXT -no edema

ANCILLARIES

- BUN 31
- K 5.0 NA 135
- CO2 25.0
- PROT/CREAT UR 0.07
- UA: no RBC, no WBC nor cast
- HGB 9.6
- PLT'S AUTO 293
- CA 8.8 01/06/2008

ANCILLARIES

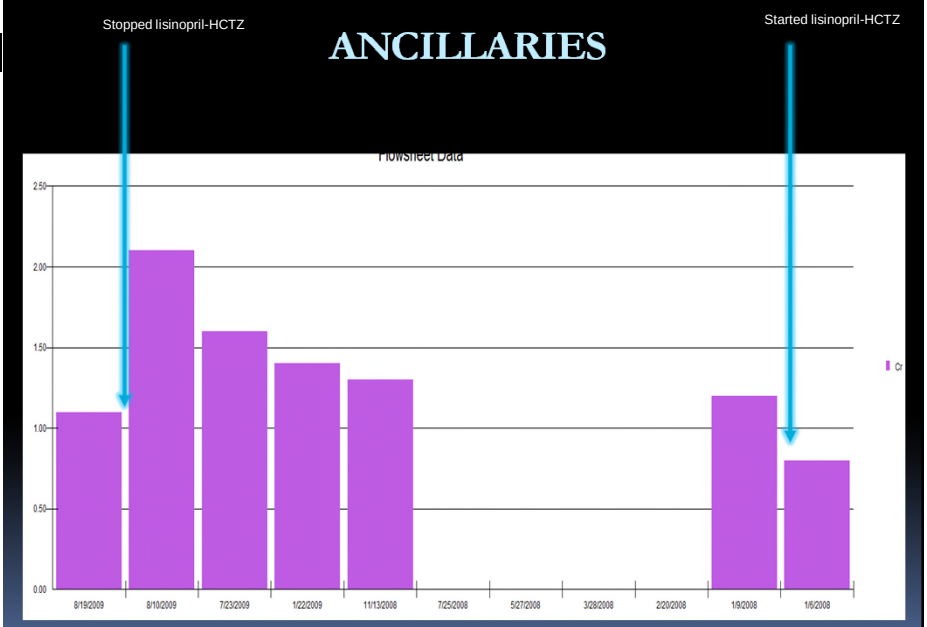

WHEN TO SUSPECT SECONDARY HTN

- Age less than 30 years in non-obese, non-black patients with a negative family history
- Severe or resistant hypertension.
- An acute rise in blood pressure over a previously stable value

Kaplan NM. *Kaplan's Clinical Hypertension, 10th ed.* Philadelphia: Lippincott Williams & Wilkins 2010:150.

WHEN TO SUSPECT SECONDARY HTN

Presence of features indicative of secondary causes

-Unprovoked or easily provoked hypokalemia

-Abdominal bruit, > 30% rise in creatinine after RAAS blockade

-Variable pressures with "5 p's" [1]

Paroxysmal HTN

Pounding Headache

Perspiration

Palpitation

Pallor

Young, WF; Mayo Clinic

Cause of Secondary Hypertension

- **Renal**
  - Renovascular HTN
  - CKD
  - Renin secreting tumors
- **Adrenal**
  - Primary Hyperaldosteronism
  - Pheochromocytoma
  - Cushing's
  - Syndrome of Apparent Mineralocorticoid Excess
- **Endocrine**
  - Thyroid
  - Primary Hyperparathyroidism
- **Genetic**
  - Liddle's syndrome
  - Gordon's syndrome
- **Drug Induced**
- **Sleep Apnea**

Secondary causes of Resistant Hypertension

	Estimated Prevalence (%)
Renal Parenchymal Disease	1-8 (depending on creatinine)
Renal artery disease	3-4
Primary aldosteronism	1.5-15
Pheochromocytoma	<0.5
Cushings	<0.5
Coarctation of the aorta	<1

Moser M & Setaro JF. N Engl J Med 2006;355:385.

ARS #1

What would you next?

A. Dupplex renal ultrasound
B. Plasma renin activity and aldosterone level
C. CTA
D. Renal angiogram
E. MRA

…case continued

- PRA: 31
- Aldosterone: 22
- Ratio: 0.7

- UTZ :The kidneys, bilaterally, are of normal size (9cm), without evidence of a mass or hydronephrosis.

ARS question #2

Which of the following is the most likely diagnosis?

A. Essential HTN
B. Primary aldosterone excess
C. Bilateral Renovascular HTN (Fibromuscular Muscular Dysplasia)
D. Renin secreting tumor

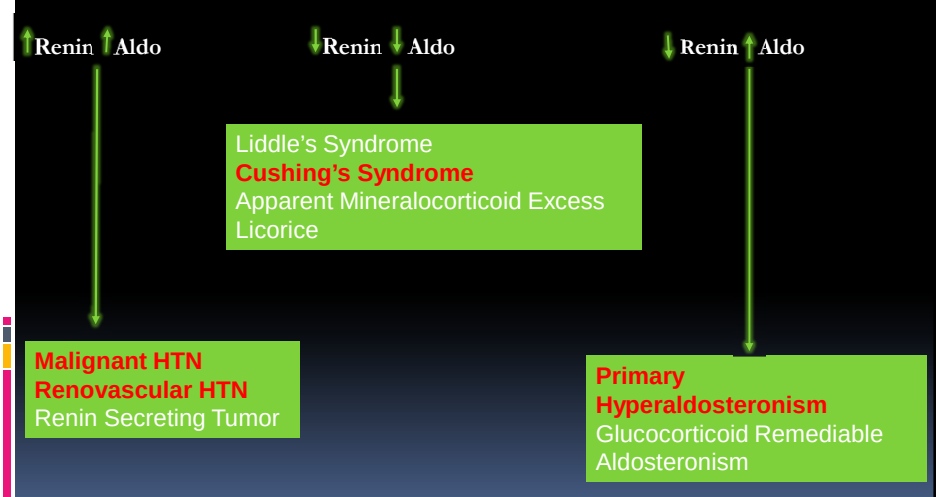

RENOVACULAR HTN

- An acute elevation in serum creatinine of at least 30 percent after administration of ACE inhibitor or angiotensin II receptor blocker
- severe hypertension in a patient with diffuse atherosclerosis, a unilateral small kidney, or asymmetry in renal size of more than 1.5 cm
- recurrent episodes of flash pulmonary edema with deteriorating renal function
- abdominal bruit

Renovascular HTN

Approximately:

- **85% Atherosclerotic disease**
- **14% Fibromuscular disease**
- **1% Other**

FIBROMUSCULAR DYSPLASIA

- Non inflammatory, non atherosclerotic disorder that leads to arterial stenosis
- F>M, young
- 35-50% bilateral renal arteries
- Presents with HTN, headache, pulsatile tinnitus, cervical bruit, stroke
- Diagnosis: Dupplex UTZ, CTA, MRA, angiography
- Treatment: medical, Percutaneous Transluminal Angioplasty, Surgery

…..Case continued

COARCTATION OF THE AORTA

- Narrowing of the descending aorta
- 4-6 percent of all congenital heart defects [1]
- M>F
- Increased in Turner's, bicuspid aortic valve, VSD, PDA, MS
- The most important non cardiac abnormality is intracerebral aneurysm

1. J Pediatr. 2008;153(6):807. Epub 2008 Jul 26

Coarctation of the Aorta

- **Mechanism of Hypertension: activated RAAS**
  Presentation: HTN in the arms with ↓ femoral pulses.
- **Diagnosis:** measurement of BP in arms and legs, interscapular murmur, CXR shows notching of posterior ribs 3-8.
- CT, MRA, echocardiography, and aortography are all useful.
- **Management:** surgery and angioplasty for patients with transtenotic gradient > 20 mmHg.
- HTN cure is age dependent; 90% cure if corrected in childhood; <50% after age 50

..case continued

- evaluated by Rheum for Takayasus/vasculitis; autoimmune work-up negative
- evaluated by neurosurgery for incidental 2 mm right cavernous carotid aneurysm, which has a <0.1% annual risk of rupture
- had echo which showed structurally normal heart
- Had angioplasty, BP controlled on single agent. Required re angioplasty after 6 mos.

PEARLS

- Always, always, always-do complete history and physical
- check renal function about a week of instituting ACEi or ARB therapy