Regional white and gray matter differences between visual vertigo patients and healthy controls: preliminary results.

Angelique VAN OMBERGEN[1], Ben JEURISSEN[2], Floris VANHEVEL[3], Jasmeen SIDHU[1], Berina IHTIJAREVIC[1], Vincent VAN ROMPAEY[4], Stefan SUNAERT[5], Paul H. VAN DE HEYNING[1,4], Paul M. PARIZEL[3] & Floris L. WUYTS[1]

(1)Antwerp University Research centre for Equilibrium and Aerospace, Department of Physics, University of Antwerp, Antwerp, Belgium
(2)Vision Lab, Department of Physics, University of Antwerp, Antwerp, Belgium
(3)Department of Radiology, Antwerp University Hospital, University of Antwerp, Antwerp, Belgium
(4)Department of Otorhinolaryngology and Head and Neck Surgery, Antwerp University Hospital & University of Antwerp, Antwerp, Belgium
(5) Department of Imaging and Pathology, Translational MRI,KU Leuven, Leuven, Belgium

Introduction

Visual vertigo (VV)[1] is a complex syndrome where patients experience discomfort, postural instability, spatial disorientation and symptom exacerbation in **disorienting visual environments** (e.g. supermarket aisles, crossroads, 3D movies, …). Logically, this has **a negative impact on the quality of life** of these patients and their social activity. After an acute vestibular loss, the majority of patients rely on visual cues for posture control and they incorporate proprioceptive cues in a later phase, a process called **sensory reweighting**[1]. However, a high visual dependency in VV patients interferes with this compensation process and therefore patients keep experiencing problems. The aim of this study was to investigate if there is a **neural correlate for this hampered compensation process** in VV patients.

Methodology

Subjects

- 5 VV patients (1 male, mean age: 48.4y ± 6.73y)
- 5 healthy controls (1 male, mean age: 50.6y ± 6.06y)

Data acquisition

- 3T MRI Tim Trio Siemens (32 channel head coil)
- Voxel size 2.5 x 2.5 x 2.5 mm3, acquisition matrix = 96 x 96, TR = 8100 ms, TE = 116 ms.
- b-values: 700, 1000 and 2800 s/mm^2, along 25, 45 and 75 non-collinear directions resp.
- Voxel-based morphometry[2] (VBM) and Diffusion Tensor Imaging[3] (DTI)

VBM data analysis

- Automated technique
- Whole-brain analysis
- Assessment of gray matter integrity.

DTI data analysis

- Manual region of interest (ROI) placement based on a priori hypothesis
- TrackVis[4] software
- White matter structures: **splenium**, **inferior longitudinal fasciculus** (ILF), **inferior fronto-occipital fasciculus** (IFOF) and **the inferior, middle and superior cerebellar peduncles** (ICP, MCP and SCP)

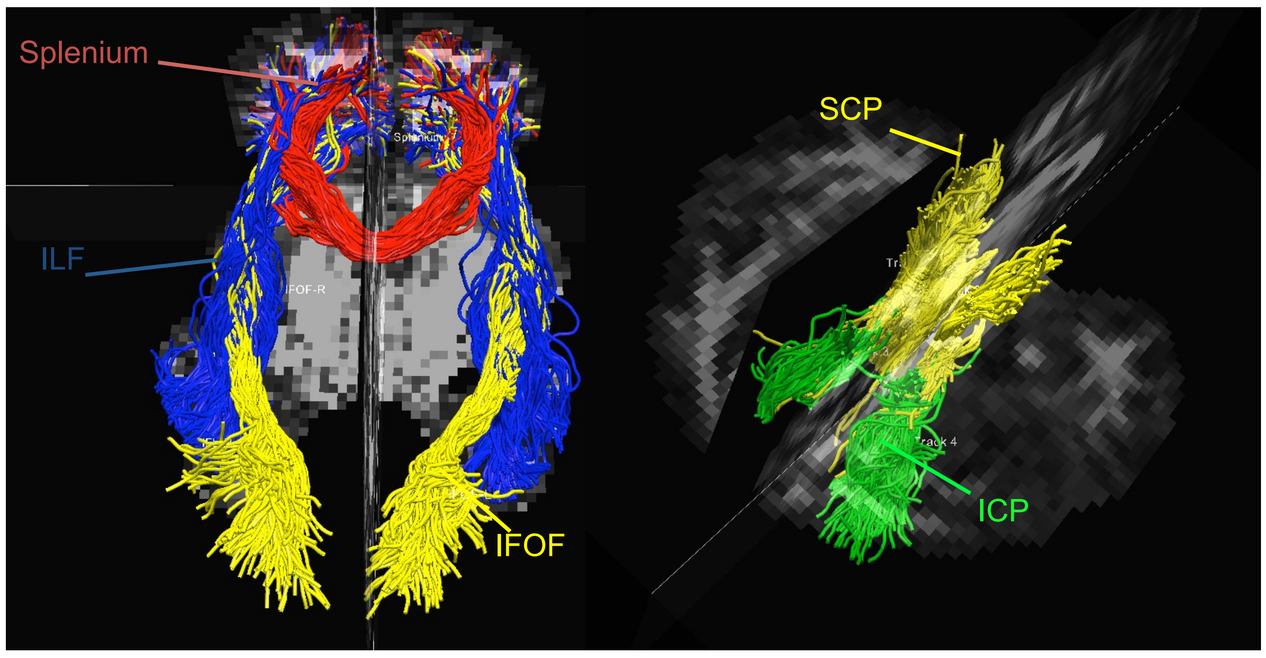

Fig 1a: The reconstructed visuospatial network in a patient.

Fig 1b: The reconstructed ICP and SCP in a patient.

Results

Gray matter

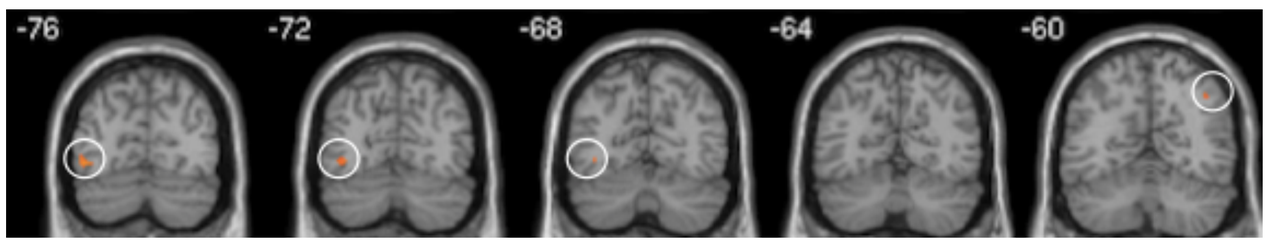

Fig 2: Coronal slices showing clusters of significant volume decrease between VV patients and healthy controls (controls>patients). Representative peak activations are listed in Table 1.

	Anatomical region	MNI coordinates[5]	Cluster	p_{UNC}-value
Decrease	Inferior occipital lobe L	x = -43.5; y = -76.5; z = -9	127	p < 0.001
Decrease	Angular gyrus R	x = 42; y =- 61.5; z = 43.5	66	p < 0.001

Table 1: Neuroanatomical regions showing a significant difference between VV patients and healthy controls. (numerical labels, x coordinates of sagittal slices; y coordinates of axial slices; z coordinates of coronal slices; L=left; R=right).

White matter

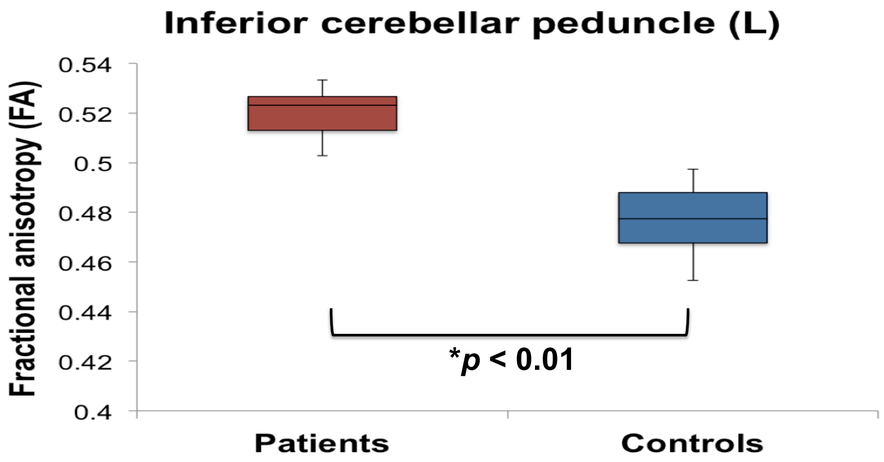

Fig 3: Boxplot showing statistically significant group differences (p<0.01) in FA (dimensionless) for the ICP in the left hemisphere.

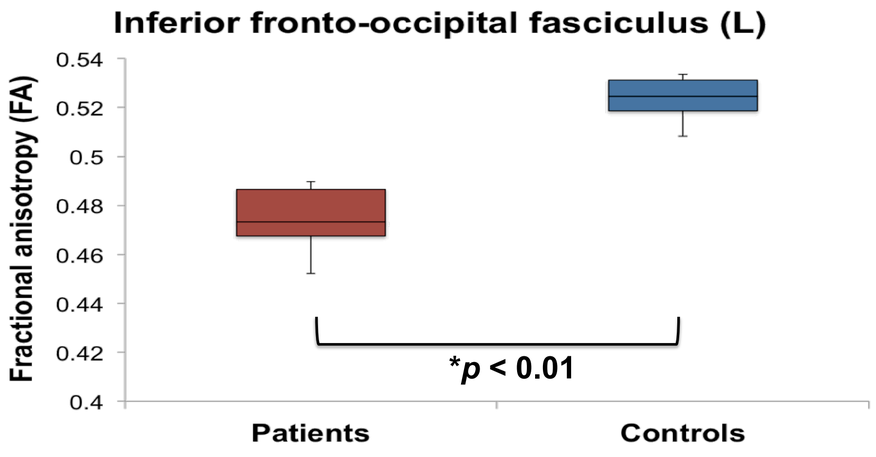

Fig 4: Boxplot showing statistically significant group differences (p<0.01) in FA (dimensionless) for the IFOF in the left hemisphere.

Discussion

- Shows a **relation between diffusion parameters** (brain connectivity) **and clinical symptoms of vertigo**.
- Decreased FA in the visuospatial network suggests a **degradation** of the **interpretation of visual info**.
- Increased FA in cerebellar projection tracts suggests **inadequate compensation** in the vestibulo-cerebellar regions?
- Differential diagnosis with **psychogenic dizziness** should be made carefully[1]!

Conclusion

- **Neurosensory mismatch** that could explain the VV symptoms and overreliance on visual cues.
- Promising results for the **use of DTI and tractography in vestibular patients**: diffusion parameters may serve as **biomarkers** in visual vertigo patients.
- **Clinical importance**!!!
- Future studies (with larger n) should elaborate these findings.

References

1. A. Bronstein (1995), *J Neurol Neurosurg Psychiatry*, 59(5), 472-6.
2. J. Ashburner et al. (2000), *NeuroImage*, 11, 805-821.
3. P.J. Basser et al. (1994), *Biophys J*, 66(1), 259-267.
4. http://www.trackvis.org, Harvard Medical School, Boston, MA, USA.
5. Montreal Neurological Institute.

Contact

Angelique Van Ombergen
Antwerp University Research center for Equilibrium and Aerospace (AUREA)
University of Antwerp
E-mail: angelique.vanombergen@uantwerp.be
LinkedIn: be.linkedin.com/pub/angelique-van-ombergen/4a/9aa/26b/
ResearchGate: https://www.researchgate.net/profile/Angelique_Van_Ombergen
Url: https://www.uantwerp.be/en/staff/angelique-vanombergen/

Acknowledgements

AVO received support from the Flanders Research Foundation (FWO Vlaanderen, Grant 11U6414N and 11U6416N).