Skip the Beat

Palpitations and Syncope in Childhood

19th Interregional Symposium

November 2, 2018

Session B, 11:15-12:30

John-Charles Loo, MD

Pediatric Cardiology, SCPMG--OC

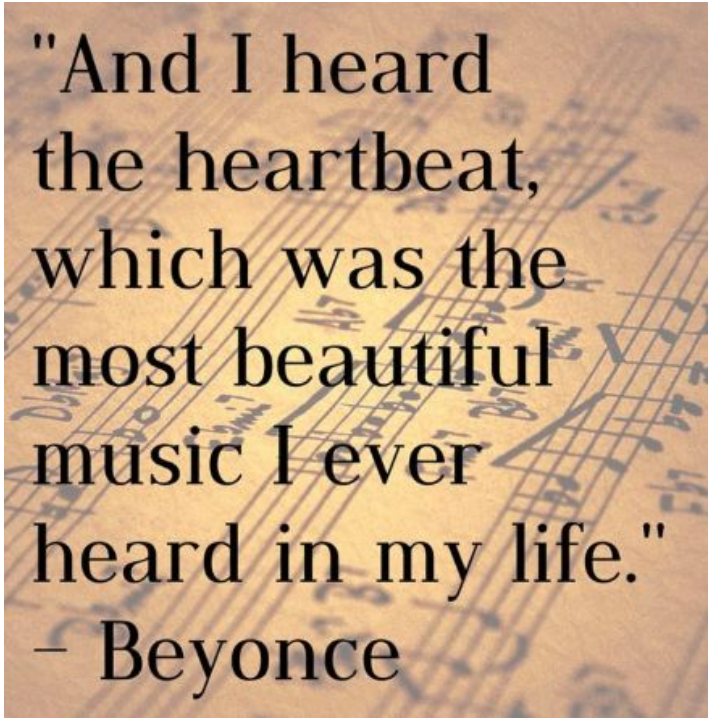
"And I heard the heartbeat, which was the most beautiful music I ever heard in my life."
– Beyonce


What makes your heart beat faster? Do more of that....

Purpose

- Demystify the pediatric cardiologist's job
- History, history, history
- Red flags
- Tools to explain diagnosis
- Reassurance with confidence
- Anticipatory guidance

Palpitations

A 14 year old female has had palpitations for many years.

What are some questions you would ask to differentiate normal physiology from pathology?

A 14 year old female has had palpitations for many years.

What does she mean by “palpitations”?

A 14 year old female has had palpitations for many years.

How long does it last?

A 14 year old female has had palpitations for many years.

Does it occur at exercise or at rest?

A 14 year old female has had palpitations for many years.

Is it related to certain situations like when nervous? At bedtime? Wakes up at night with it? When she stands up?

A 14 year old female has had palpitations for many years.

How does it stop?

A 14 year old female has had palpitations for many years.

Palpitations are described as a single thump or skipped beat. It occurs 2-3 times per week. It occurs usually while on her phone or lying down at night for bed. She plays soccer for club and her school, and it has never occurred during those or during PE. One time she had several of these over an hour period. It usually “catches her breath”, but just for the moment that the beat occurs.

A 14 year old female has had palpitations for many years.

Palpitations are described as a single thump or skipped beat. It occurs 2-3 times per week. It occurs usually while on her phone or lying down at night for bed. She plays soccer for club and her school, and it has never occurred during those or during PE. One time she had several of these over an hour period. It usually "catches her breath", but just for the moment that the beat occurs.

Palpitations

- Order of symptoms, focus on the first (rule of 1)
- Single pound or skip vs rapid beat?
- How does it stop? Gradual or abrupt?
- Exercise or at rest?
- How often?
- If the patient is anxious, that’s what it is.

Palpitations

The feeling of an abnormal heart beat

fast, heavy, or skipped (irregular)

Consider “normal” first

1. Normal is usually not felt
2. Slow is not felt either
3. Fast or extra is felt

So what are we looking for?

Fast or Extra (which is a single extra fast)

The diagnosis will either be:

Normal (physiologic), sinus rhythm or tachy

Normal (extra, but benign)

Abnormal, tachycardia

Normal and abnormal

- Normal or physiologic
  - Sinus rhythm
  - Sinus tachycardia
  - Premature Atrial/Junctional/Ventricular Contractions
- Abnormal
  - SVT/WPW
  - Ventricular arrhythmia

AGE	Approximate Weight Kg	Systolic Blood Pressure mmHg	Heart Rate Beats/minute	Respiratory Rate Breaths/minute
Term	3.5	60-105	110-170	25-60
3 months	6	65-115	105-165	25-55
6 months	8	65-115	105-165	25-55
1 year	10	70-120	85-150	20-40
2 years	13	70-120	85-150	20-40
4 years	15	70-120	85-150	20-40
6 years	20	80-130	70-135	16-34
8 years	25	80-130	70-135	16-34
10 years	30	80-130	70-135	16-34
12 years	40	95-140	60-120	14-26
14 years	50	95-140	60-120	14-26
17+ years	70	95-140	60-120	14-26

Premature ectopic beats

- PAC = premature atrial contraction
  - Above the AV node
  - Very common in newborns
- PJC = premature junctional contraction
  - At the AV node
  - Less common
- PVC = premature ventricular contraction
  - Below the AV node
  - <10% frequency benign

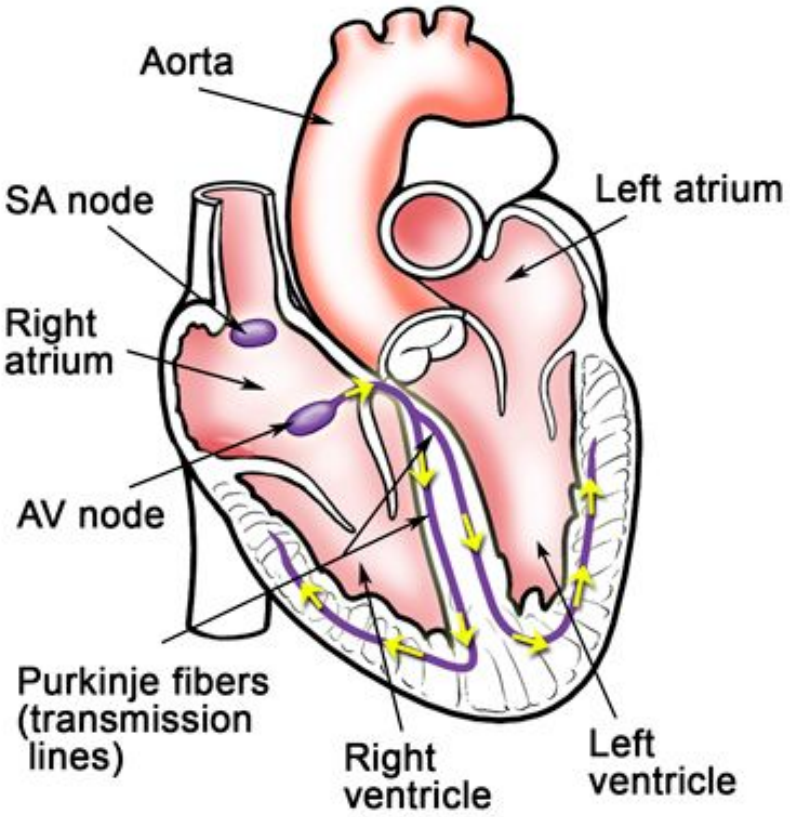

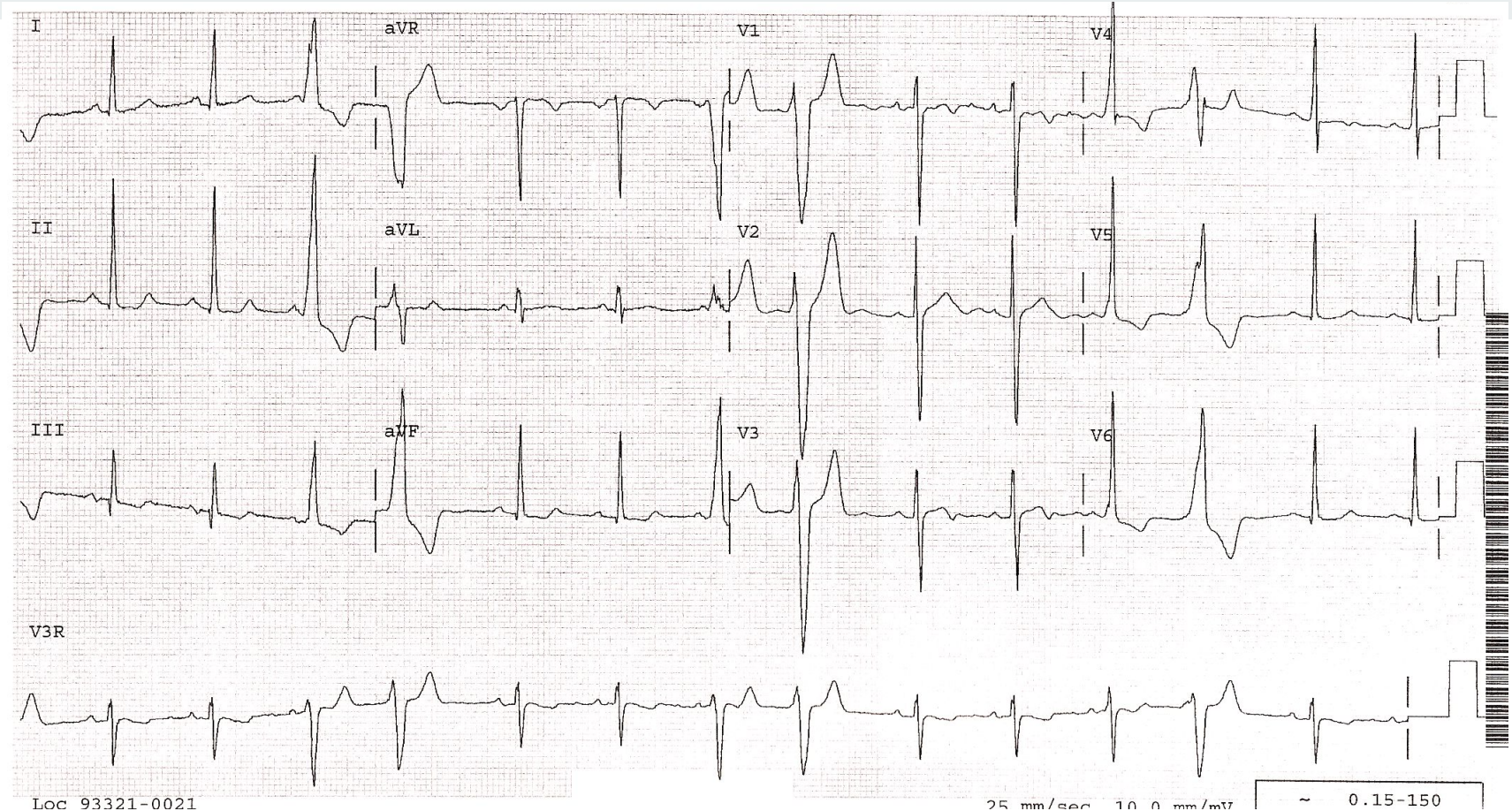
I
aVR
V1
V4
II
aVL
V2
V5
III
aVF
V3
V6
V3R
Loc 93321-0021
25 mm/sec 10.0 mm/mV
~ 0.15-150

Premature Ventricular Contraction

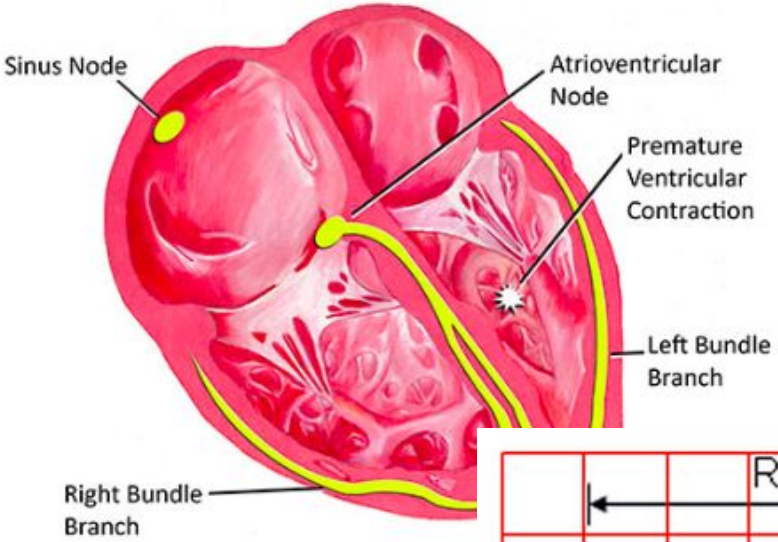

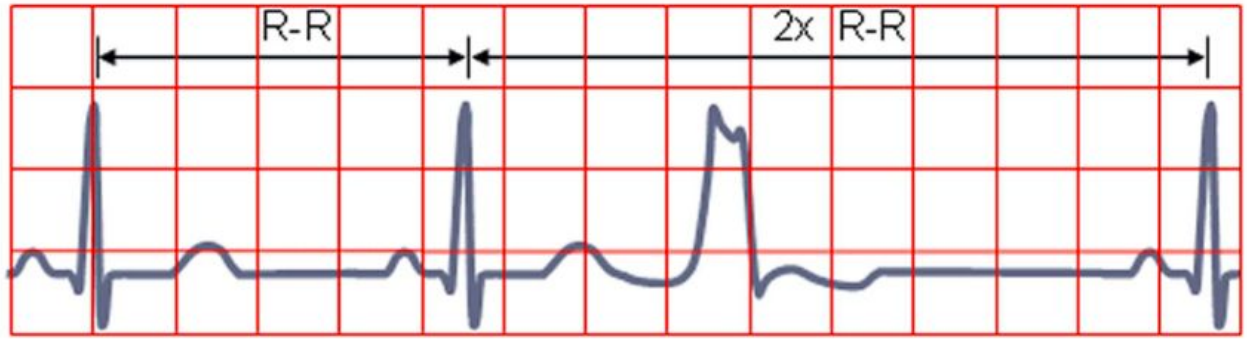

Time interval between normal R peaks is a multiple of R-R interval

PVCs

- Feels like a single thump, which is the beat after the PVC
- Sometimes “catches my breath”
- Very common, newborns and teens, but not everyone feels them
- Increased frequency after exercise is normal

Asymptomatic normal heart rhythms

- Sinus arrhythmia is normal variation of sinus rate with respiration.
- Sinus bradycardia is <90 in neonate and <60 in older, but much variation is seen
- Wandering atrial pacemaker is shift in pacemaker from sinus node to another. It is a normal variant.

Jack is a 15 year old male with palpitations

- The first episode occurred 2 months ago.
- Occurs every 2-3 weeks for a total of 6-7 episodes. The most recent episode was 2 weeks ago.
- Episodes generally occur while playing volleyball, typically with jumping or landing.
- Additional symptoms occurring after the onset include: dizziness.
- It lasts 3-8 minutes. The onset is abrupt and offset is abrupt.
- It is too fast to count.

Jack is a 15 year old male with palpitations

- The first episode occurred 2 months ago.
- Occurs every 2-3 weeks for a total of 6-7 episodes. The most recent episode was 2 weeks ago.
- Episodes generally occur while playing volleyball, typically with jumping or landing.
- Additional symptoms occurring after the onset include: dizziness.
- It lasts 3-8 minutes. The onset is abrupt and offset is abrupt.
- It is too fast to count.

Natalie is a 9 year old with palpitations

- She had an episode of palpitations two days ago while at the beach.
- She was building sand castles and felt her heart beating fast. She dried off, ate lunch, and mother noticed her heart beating fast also.
- Later she went home. Her father also felt her heart beat and noted it to be fast. She was taken to see the doctor.
- The total time was about 4 hours. She was seen by her pediatrician, and HR was 180.
- She was told to take a deep breath and hold it for a little while. After a few deep breaths, it came down to 80-100.

Natalie is a 9 year old with palpitations

- She had an episode of palpitations two days ago while at the beach.
- She was building sand castles and felt her heart beating fast. She dried off, ate lunch, and mother noticed her heart beating fast also.
- Later she went home. Her father also felt her heart beat and noted it to be fast. She was taken to see the doctor.
- The total time was about 4 hours. She was seen by her pediatrician, and HR was 180.
- She was told to take a deep breath and hold it for a little while. After a few deep breaths, it came down to 80-100.

Supraventricular Tachycardia

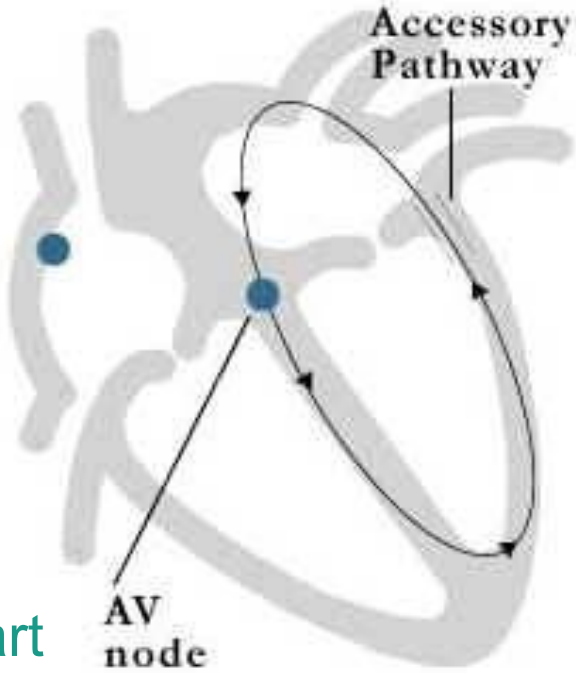

- Rate usually >160
- In young infants, rate is 200-300
- Offset is sudden
- If SVT sustained (hours), may have heart failure symptoms
  - Less than that is well tolerated

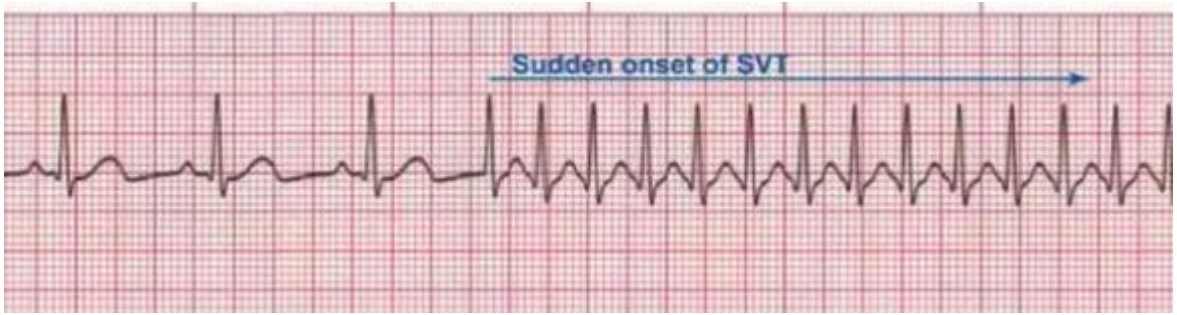
Sudden onset of SVT


ADENOSINE

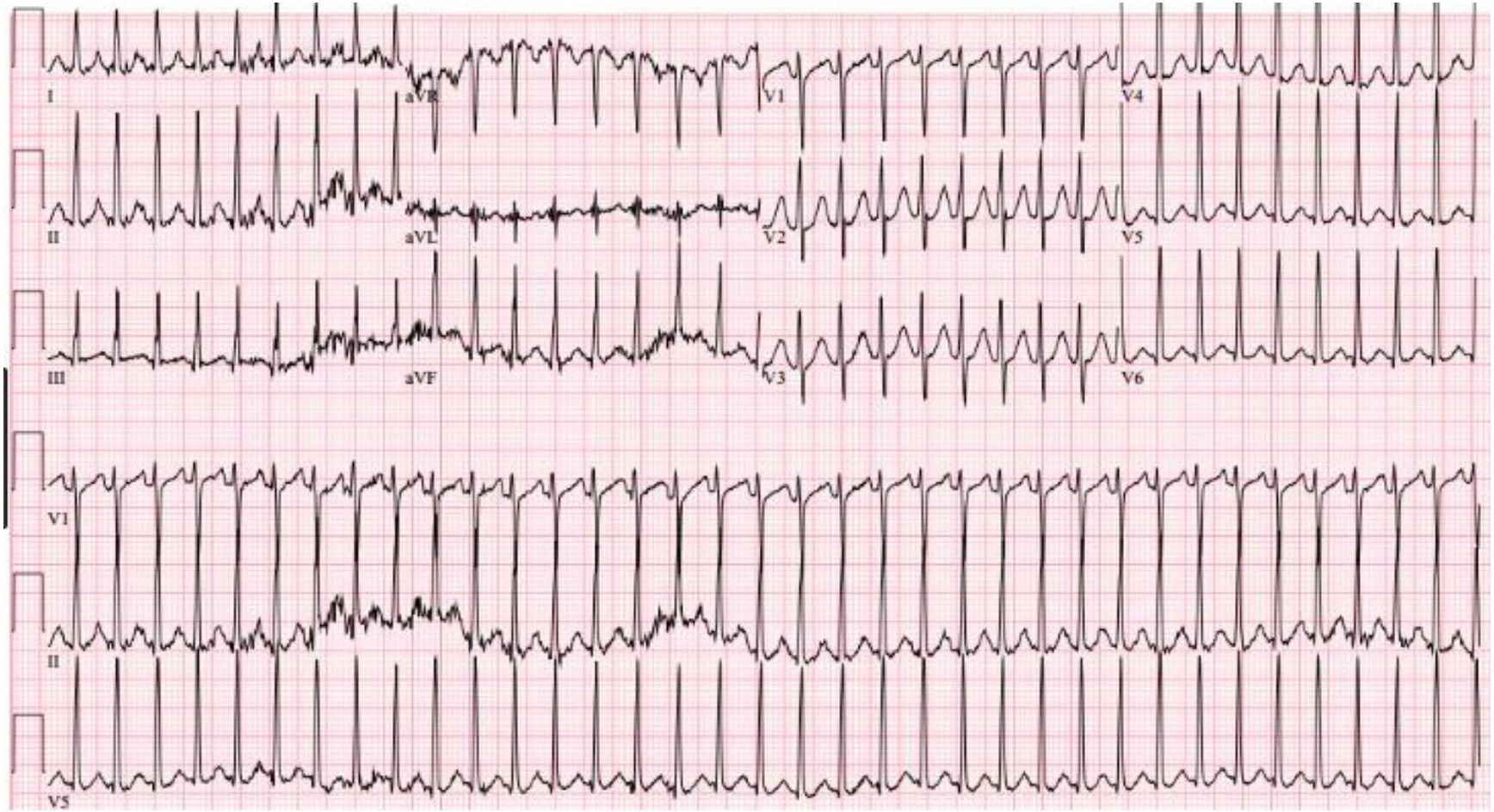
I
aVR
V1
V4
II
aVL
V2
V5
III
aVF
V3
V6
V1
II
V5

Orthodromic AVRT

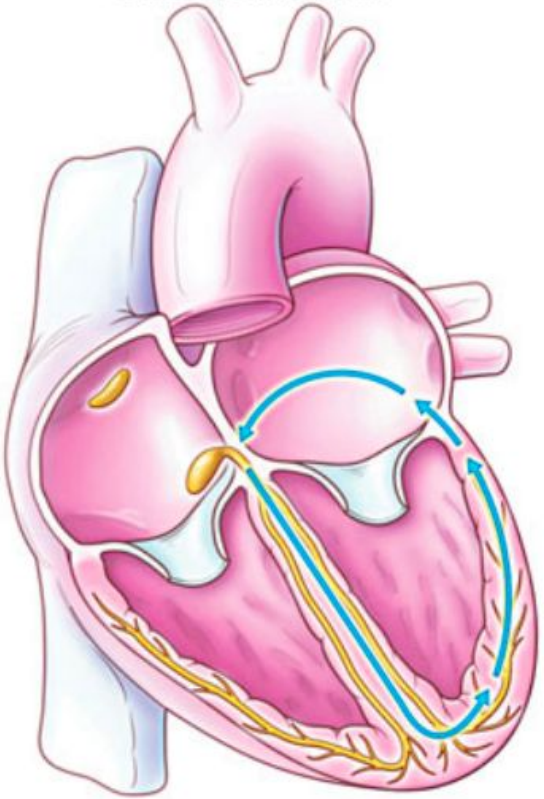

SVT

- “Is there anything you can do to stop it?”
- Vagal maneuvers to break SVT
  - Breath holding, ice water, valsalva, posture

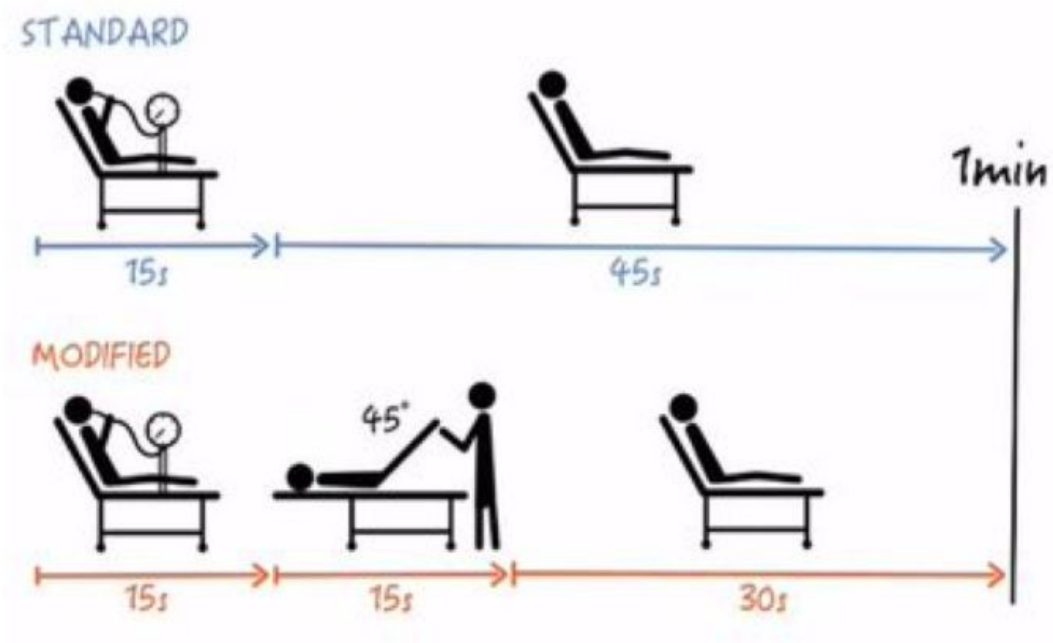

Figure 3. The Modified Valsalva Maneuver

Types of SVT

Supraventricular Tachycardia Organized by Anatomic Origin

Sinoatrial nodal origin

- Sinoatrial nodal reentry tachycardia

Atrial origin

- Automatic atrial tachycardia
- Ectopic (unifocal) atrial tachycardia
- Multifocal atrial tachycardia
- Atrial flutter with rapid ventricular response
- Atrial fibrillation with rapid ventricular response

Atrioventricular nodal origin (junctional tachycardia)

- Atrioventricular reentrant tachycardia
- Atrioventricular nodal reentry tachycardia
- Junctional ectopic tachycardia
- Persistent junctional reciprocating tachycardia

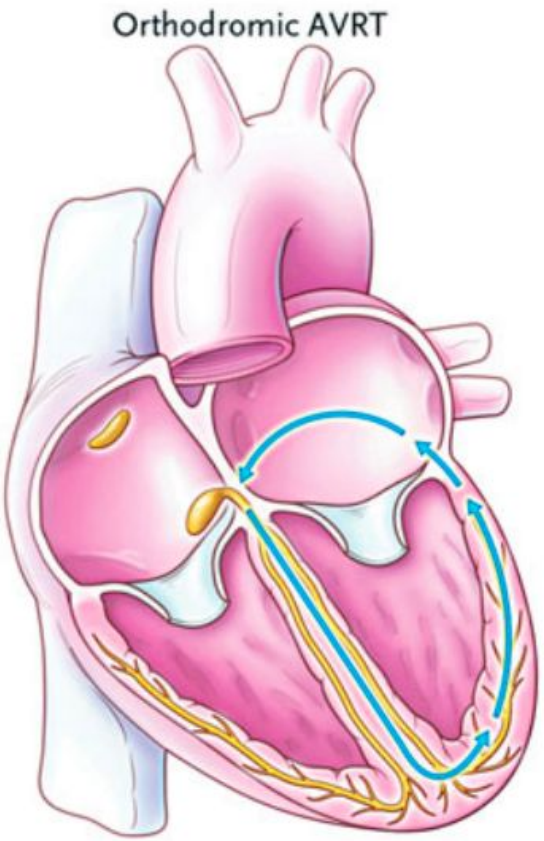
Orthodromic AVRT

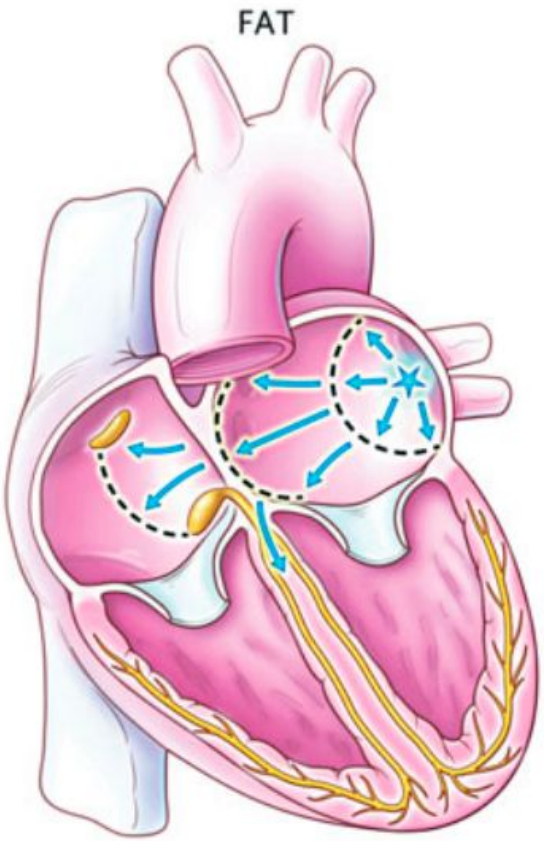
FAT

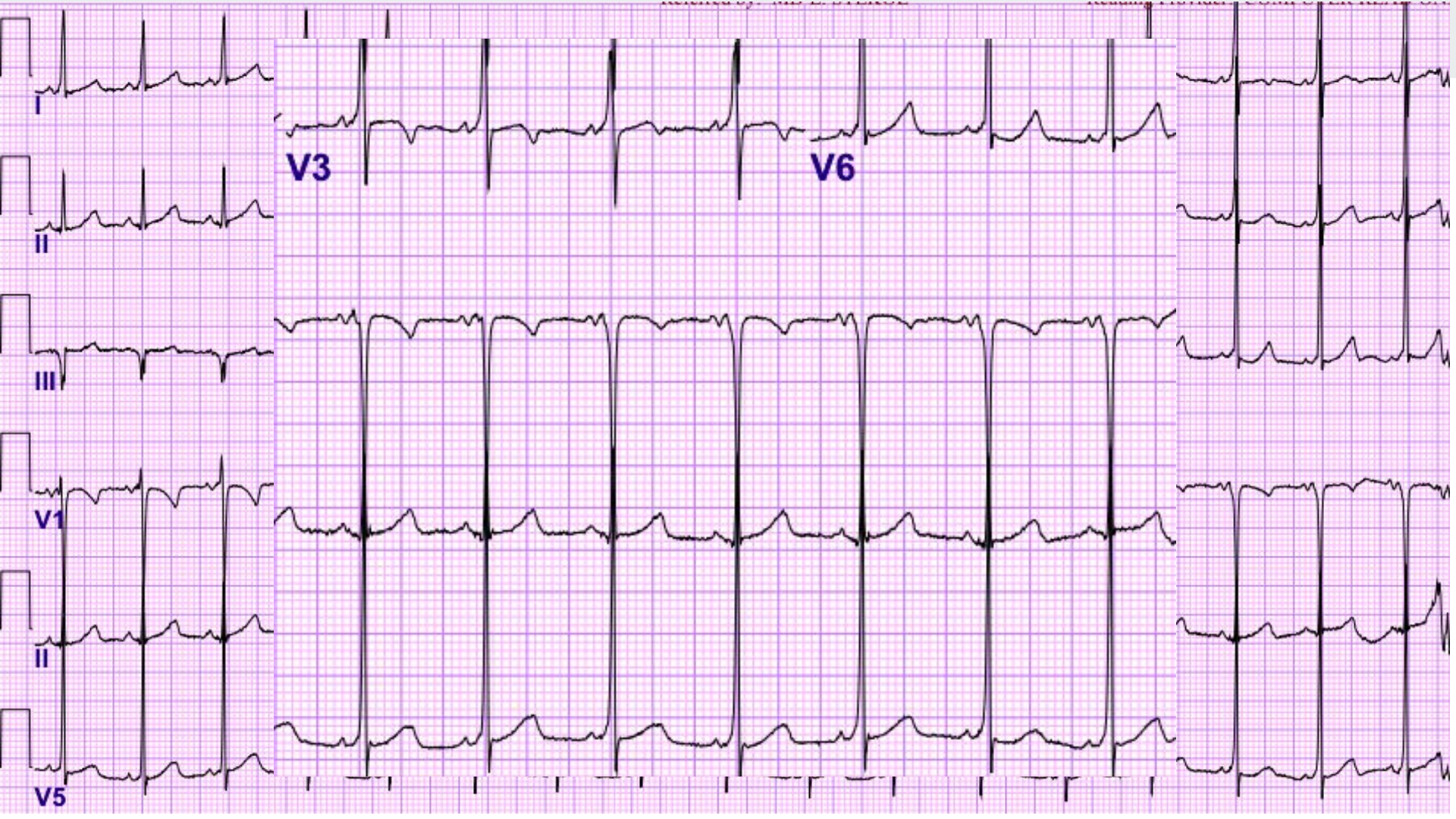
I
II
III
V1
II
V5
V3
V6

Ventricular tachyarrhythmias

- At least 3 ventricular beats at >120 bpm
- Much less common than SVT
- “Increased” frequency (especially benign ones)
- Ventricular tachycardia vs accelerated ventricular rhythm
  - Sometimes associated with myocarditis, anomalous coronary, ARVD, MVP, tumor, cardiomyopathy, long QT, WPW, drugs, post surgical

Palpitations--Instructions for families

- Teach them how to take a pulse, give ranges
  - Rates can go up to 140 physiologically (emotion)
  - Gradual decrease over a few minutes
  - Concern for faster rates or sudden offset
- Hydration, avoid caffeine
- Reassurance: symptoms may resolve or feel more normal
- Return for persistent symptoms or clearly not anxiety/stress

What if I think they might have something...

??????????

ER in past...

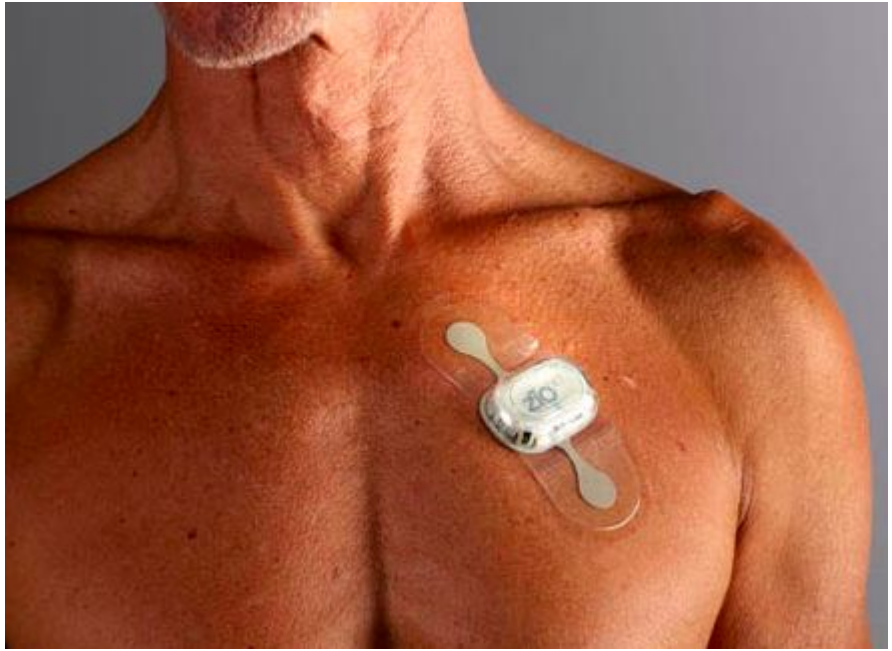


STARBUCKS
Decaf
Shots
Syrup
Milk
Custom
Drink
MHC
STARBUCKS
Decaf
Shots
Syrup
Milk
Custom
Drink
MCL

Syncope

Syncope

A 15 year old female has episodes of syncope…

--what do we do next?

Syncope

A 15 year old female has episodes of syncope…

1. Obtain an ECG
2. Order a holter monitor
3. Order an echocardiogram
4. Obtain more history

Syncope

A 15 year old female has episodes of syncope…

1. Obtain an ECG
2. Order a holter monitor
3. Order an echocardiogram
4. Obtain more history!

A 15 year old female has syncope

- Symptoms have occurred over the last year.
- Once while playing soccer she played the entire game. Near the end, she headed the ball, she saw bright dots, got dizzy, lost her balance, and fell. Vision was black but she could still hear. She had something to drink and felt better.
- One time she took a hot shower for 20 minutes. She got out, bent down, and when she stood back up, she felt dizzy, vision dimmed and then went black, and she passed out for a few seconds.
- Another time while having hair brushed, she got very dizzy with vision changes.
- She gets dizzy upon standing quickly, especially in am.
- Diet/day: 2 cups of water. 1 cup of juice. 2 meals a day, skipping breakfast.

How many episodes of syncope?

Are there any concerning details of the history?

What are the reassuring features?

A 15 year old female has syncope

- A few episodes over the last year.
- Once while playing soccer she played the entire game. Near the end, she headed the ball, she saw bright dots, got dizzy, lost her balance, and fell. Vision was black but she could still hear. She had something to drink and felt better.
- One time she took a hot shower, 20 minutes. She got out, bent down, and when she stood back up, she felt dizzy, vision dimmed and then went black, and she passed out for a few seconds.
- Another time while having hair brushed, she got very dizzy with vision changes.
- She gets dizzy upon standing quickly, especially in am.
- Diet/day: 2 cups of water. 1 cup of juice. 2 meals a day, skipping breakfast.

A 15 year old female has syncope

- A few episodes over the last year.
- Once while playing soccer she played the entire game. Near the end, she headed the ball, she saw bright dots, got dizzy, lost her balance, and fell. Vision was black but she could still hear. She had something to drink and felt better.
- One time she took a hot shower. 20 minutes. She got out, bent down, and when she stood back up, she felt dizzy, vision dimmed and then went black, and she passed out for a few seconds. She spontaneously recovered.
- Another time while having hair brushed, she got very dizzy with vision changes.
- She gets dizzy upon standing quickly, especially in am.
- Diet/day: 2 cups of water. 1 cup of juice. 2 meals a day, skipping breakfast.

Table 1. Etiologies Of Syncope

Cardiac Causes	Noncardiac Causes
Structural • Hypertrophic cardiomyopathy • Anomalous coronary artery* • Myocarditis* • Pericarditis* • Valvular dysfunction* **Dysrhythmias** • Commotio cordis* • Long QT syndrome • Wolff-Parkinson-White syndrome • Supraventricular tachycardia • Brugada syndrome • Short QT syndrome* • Heart block • Sick sinus syndrome* • Arrythmogenic right ventricular dysplasia*	• Neurocardiogenic/vasovagal (most common) • Postural orthostatic tachycardia syndrome • Psychogenic pseudosyncope • Drugs and toxins* • Metabolic derangements, hypoglycemia • Breath-holding spells • Seizure • Trauma • Pregnancy • Pulmonary hypertension* • Pulmonary embolism*

One point:

Is it vasovagal or not?

What is vasovagal syncope?

Vasovagal syncope

"Aka"

- Neurocardiogenic syncope
- Orthostatic hypotension
- Postural hypotension
- Dysautonomia

Related: Postural Orthostatic Tachycardia Syndrome

Vasovagal syncope

Simply put...

“I stood up, I got dizzy, I passed out”

Vasovagal syncope

How does it happen?

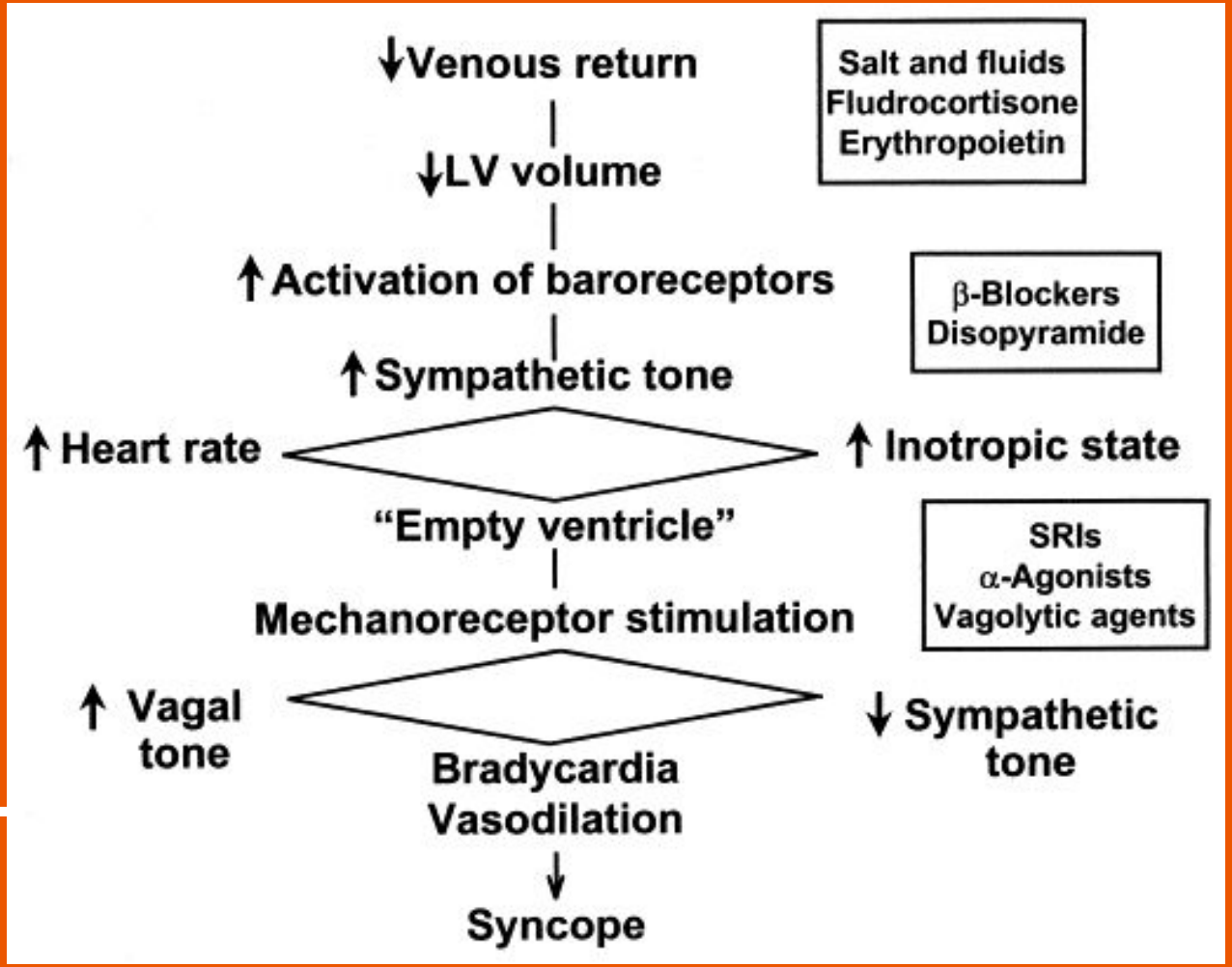

Am J of Cardiol

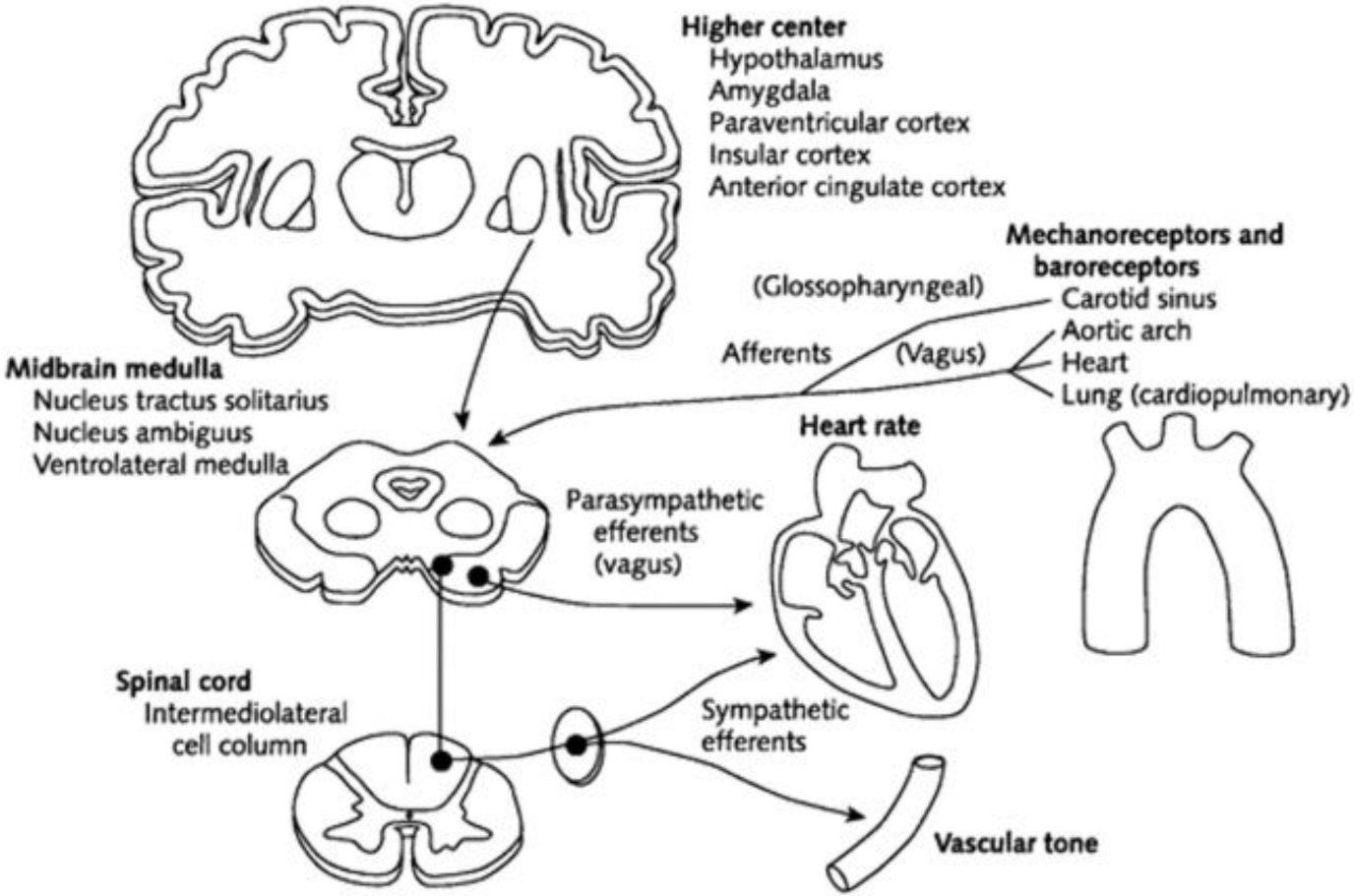
Higher center
Hypothalamus
Amygdala
Paraventricular cortex
Insular cortex
Anterior cingulate cortex
Mechanoreceptors and baroreceptors
(Glossopharyngeal)
Carotid sinus
Aortic arch
Afferents
(Vagus)
Heart
Lung (cardiopulmonary)
Midbrain medulla
Nucleus tractus solitarius
Nucleus ambiguus
Ventrolateral medulla
Heart rate
Parasympathetic efferents (vagus)
Spinal cord
Intermediolateral cell column
Sympathetic efferents
Vascular tone

Annals of IM

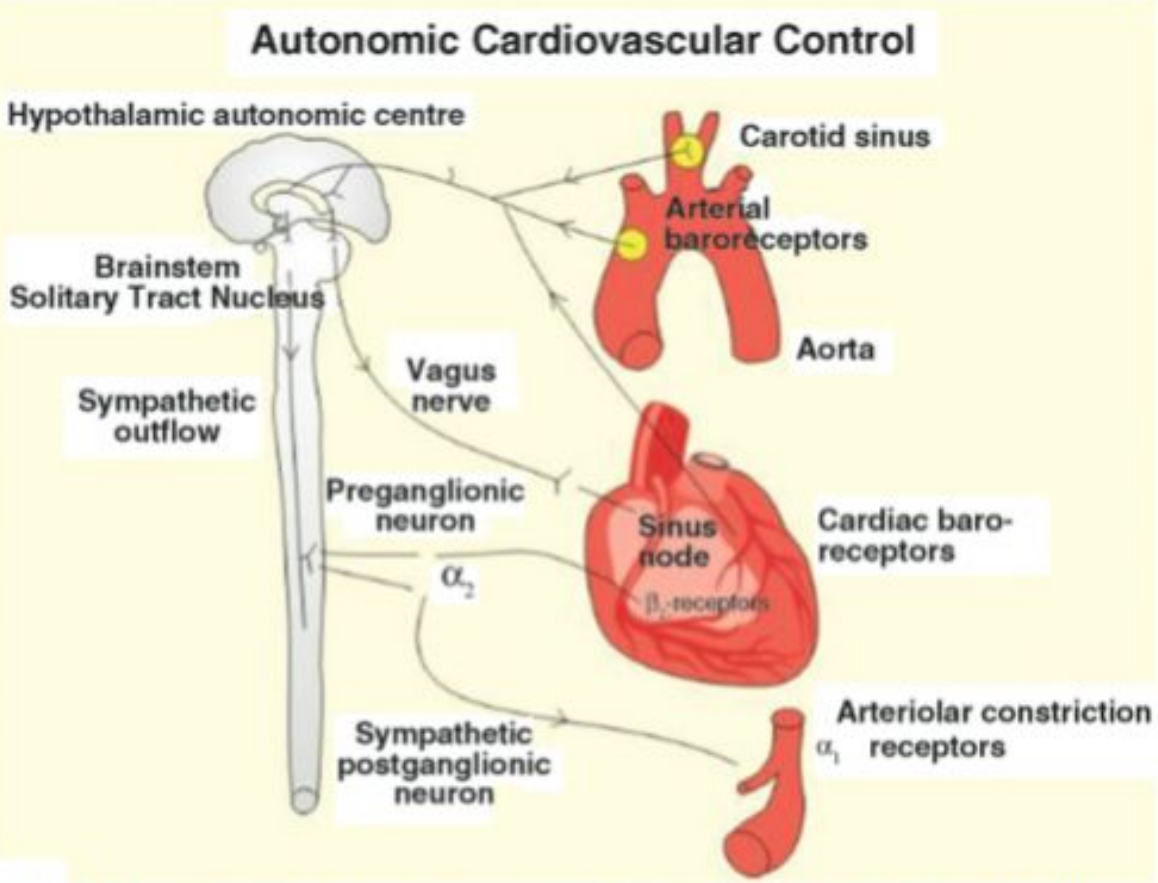

Figure 1. Reprinted from Chapter 6: The Autonomic Nervous System and Disorders. In: Paulev PE, Zubieta-Calleja G. *New Human Physiology: Textbook in Medical Physiology and Pathophysiology: Essentials and Clinical Problems.* Available online at: http://www.zuniv.net/physiology/book/chapter6.html.

The simple minded cardiologist thinks of it this way:

1. Stand up, blood goes to legs
2. Less blood to the head
3. You get dizzy, you pass out

Vasovagal

So blood vessels and the nerves controlling the blood vessel and blood pressure, must be in concert in order to not pass out.

Vaso = vessel

Vagal = vagus nerve, autonomic, automatic, or parasympathetic nervous system

Syncope Questions

- Do you get dizzy when you stand up quickly
- Is it better when you lie down or stand slowly?
- Can you avoid passing out?
- Do you fully pass out or can you still hear?
- “Was it a hot day”
- “Did you eat or drink less that day”
- “Were you sick that day”

To worry or not to worry...

- Postural, not worried
- Common triggers:

Church	**Health class**	**Pain (head, stomach)**
Seeing blood	**Hair brushing**	**Reaching or head turn**
Micturation	**Defecation**	**Shower**
Choir		

- Dizziness and syncope are of minimal concern unless it is during exertion or palpitations precede it

Table 3. "Red Flags" And "Green Lights" In Patients With Syncope

Red Flags	Green Lights
• Multiple episodes in a short time period • Associated chest pain • Episode occurred during exercise or while sitting • Family history of cardiac disease, deafness, or sudden death	• Episode occurred during standing, in a hot environment, after poor oral intake, or while ill • Normal electrocardiogram and negative pregnancy test • Normal physical examination • Patient is at baseline on presentation • Preceding symptoms include dizziness, visual changes, nausea, or diaphoresis

Physical exam?

Vital signs:

- Orthostatic heart rate--20 bpm
- Blood pressure--20/10

Cardiac exam

- Murmur increases while standing

Most times history and exam are enough:

Vasovagal syncope

Vasovagal (pre)syncope recommendations

- Salt intake
  - Electrolyte drinks
  - Gatorade, G2, Powerade, Powerade No Sugar
  - Add a little salt to veggies, bag of chips, salt tablets
- Positional awareness
  - Stand slowly
  - Sit or lie down if dizzy
  - Don’t stand for long periods
- Hand grip, elbow flex, cross legs
- Sleep on elevated pillows, compression socks/stockings

Bottom line - syncope

- It’s almost always vasovagal
- If you think it’s vasovagal, I agree
- Prodrome is very reassuring
- Concerning symptoms can usually be explained with more detail
- Exertional syncope is concerning (overexertion)

Who should get an EKG?

“All” patients with syncope should have an EKG

Who should get an EKG? Why?

What cardiac diagnoses may not be obvious by exam but are obvious by EKG?

- Long QT
- Hypertrophic Cardiomyopathy
- Heart Block
- Brugada Syndrome
- Arrhythmogenic right ventricular dysplasia

When to worry

- “Never” -- except when something’s weird
- Convincingly reassuring the family
  - Up to 1 out of 3 children pass out. My wife and son both passed out in front of me. Some pass out when they see blood.
  - Explain physiology
  - Treatment plan
  - Things to watch for: no prodrome, palpitations
  - Let them play

Beyond Vasovagal Syncope

Cardiac syncope

POTS

--Postural Orthostatic Tachycardia Syndrome

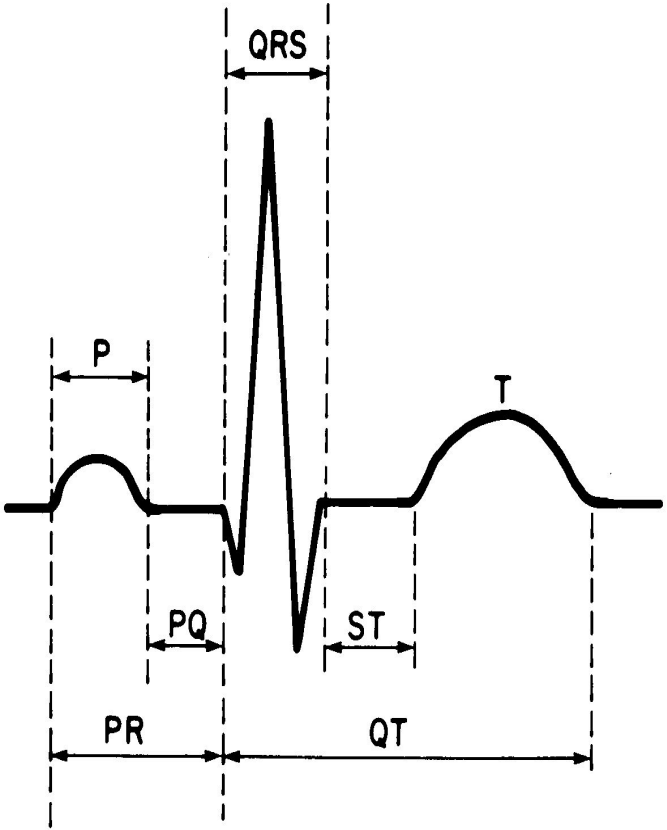

1. Rate
2. P wave
   a. axis
   b. Ht
   c. Width
3. PR interval
4. Q wave
5. QRS
   a. Axis
   b. Height
   c. width
6. ST segment
7. QT interval
8. T wave

“Borderline prolonged QT interval”

=

NORMAL

QTc

- Bazett's Formula
- QTc should be <450
- Use lead II
- Use RR interval preceeding QT

$$QTc = \frac{QT\ measured}{\sqrt{RR\ interval}}$$

$$QTc = \frac{QT\ measured}{\sqrt{RR\ interval}}$$

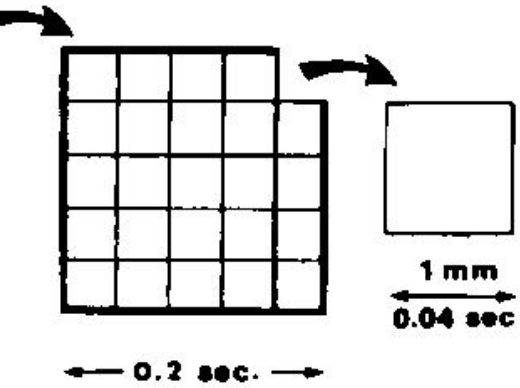

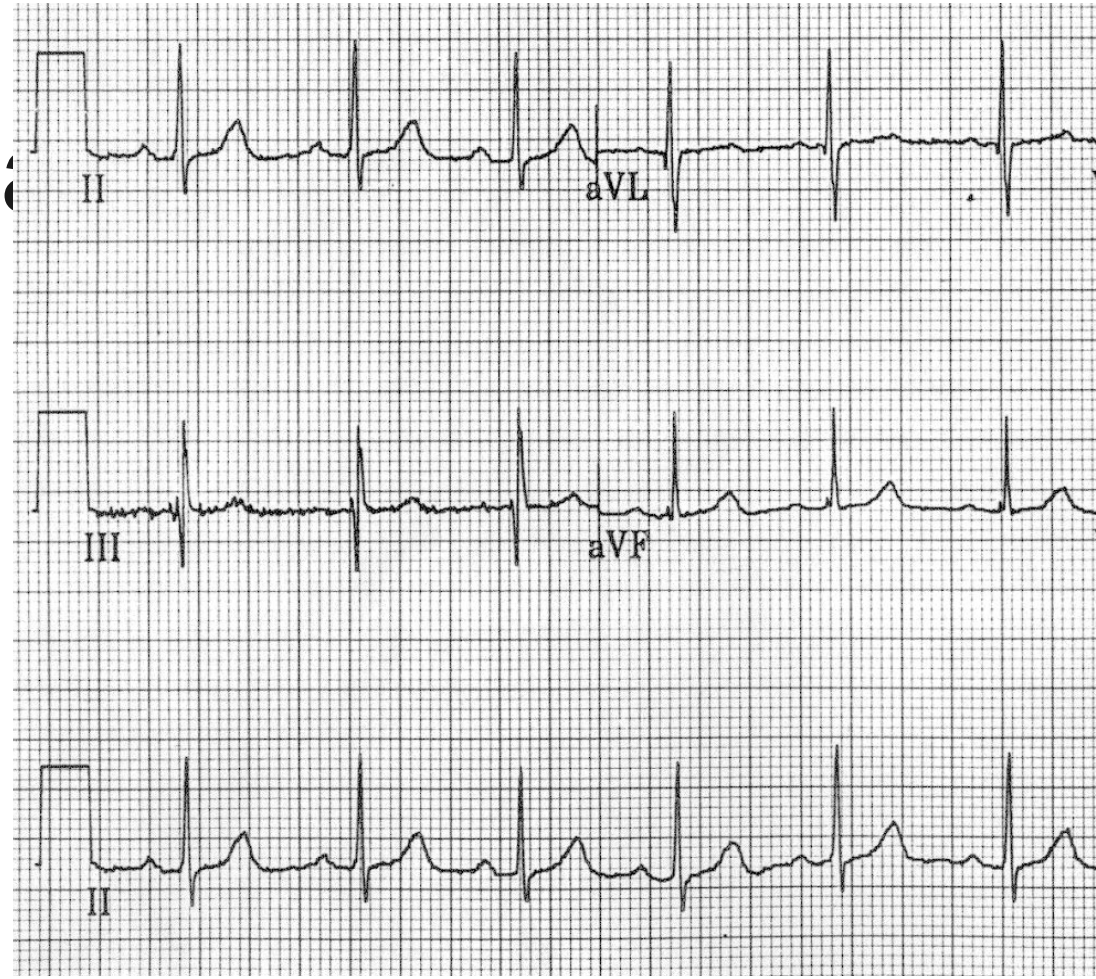

$$QTc = \frac{QT\ measured}{\sqrt{RR\ interval}}$$

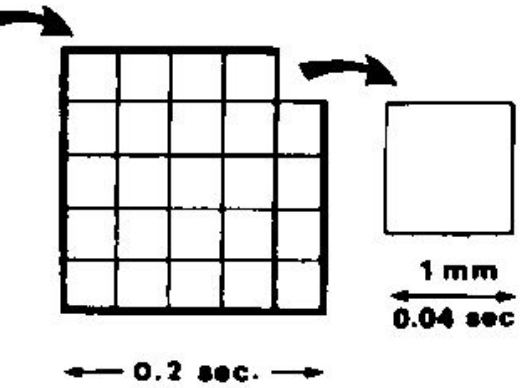

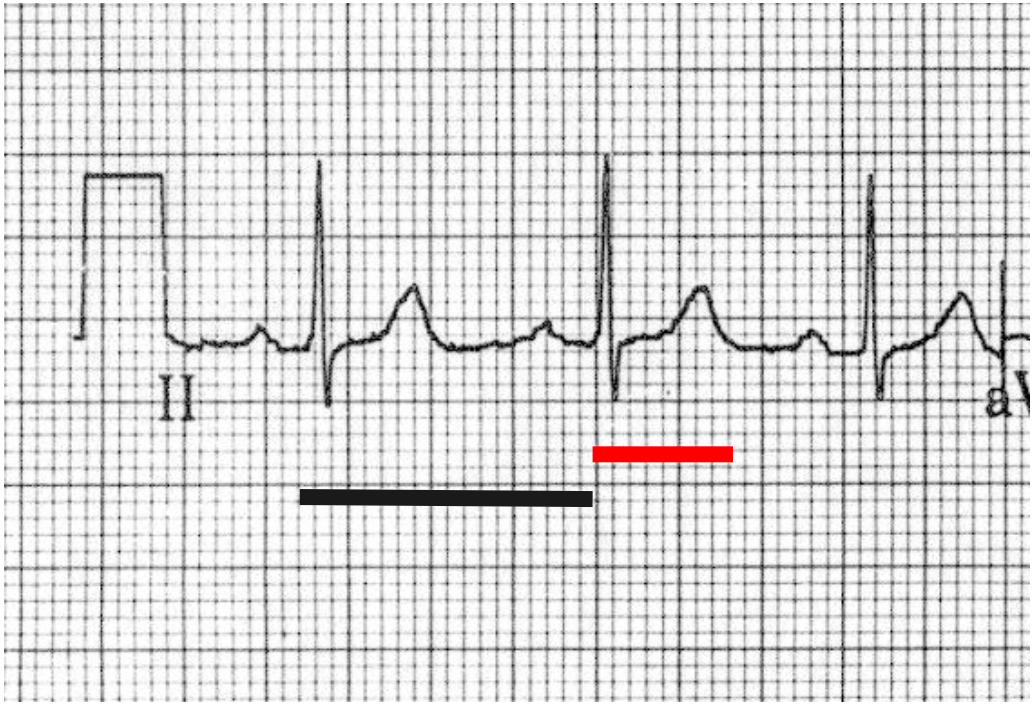

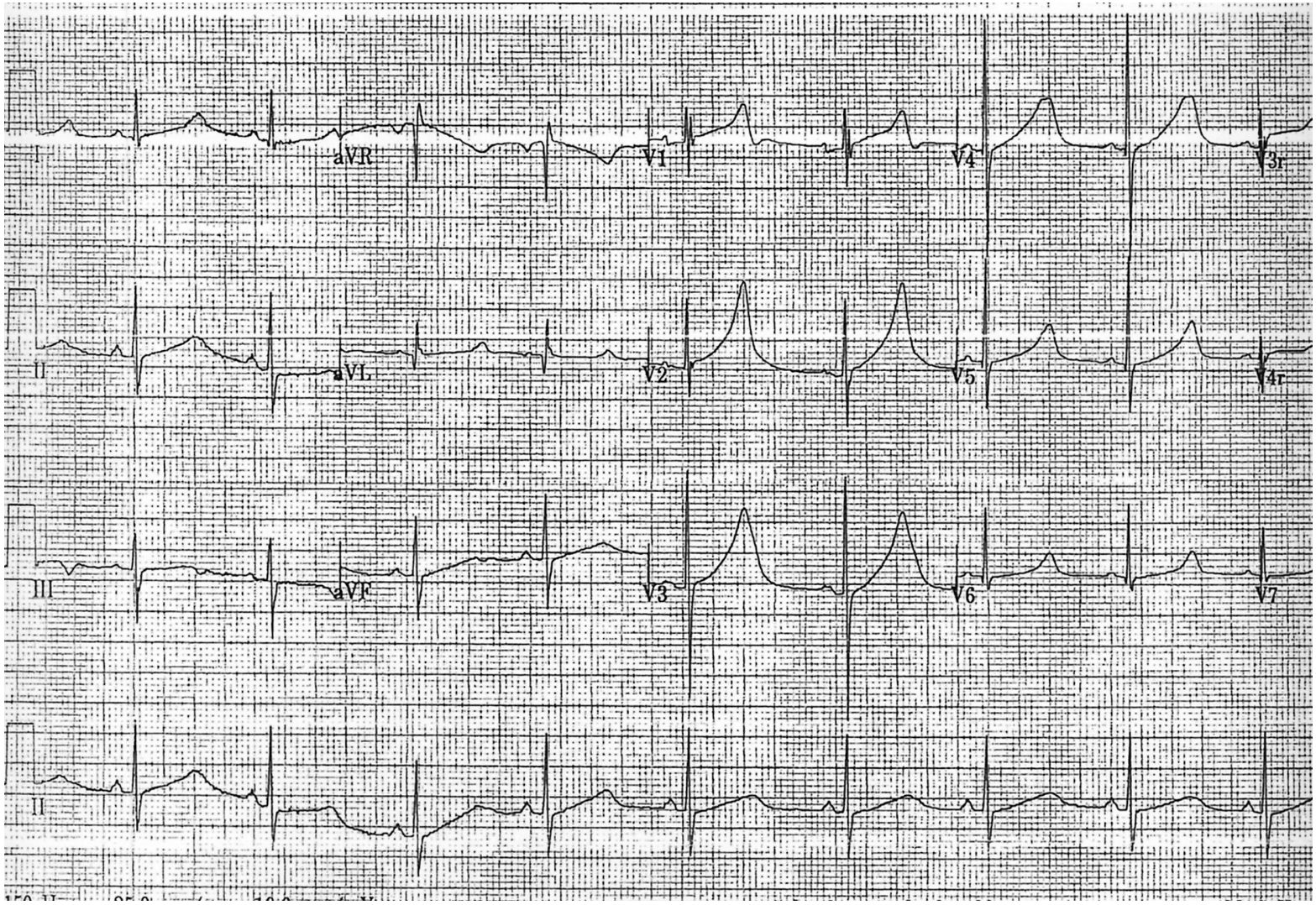
I
aVR
V1
V4
V3r
II
aVL
V2
V5
V4r
III
aVF
V3
V6
V7
II

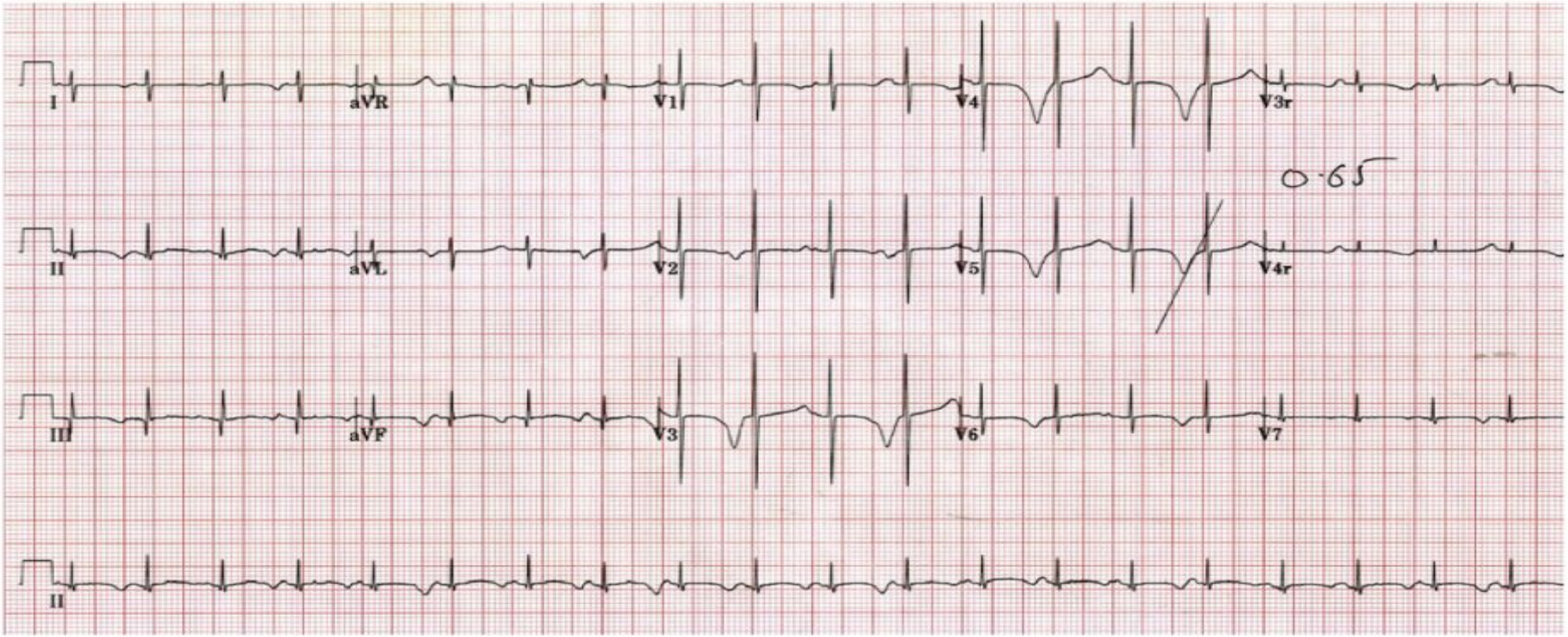
I
aVR
V1
V4
V3r
0·65
II
aVL
V2
V5
V4r
III
aVF
V3
V6
V7
II


I
AVF
150
100
50
0

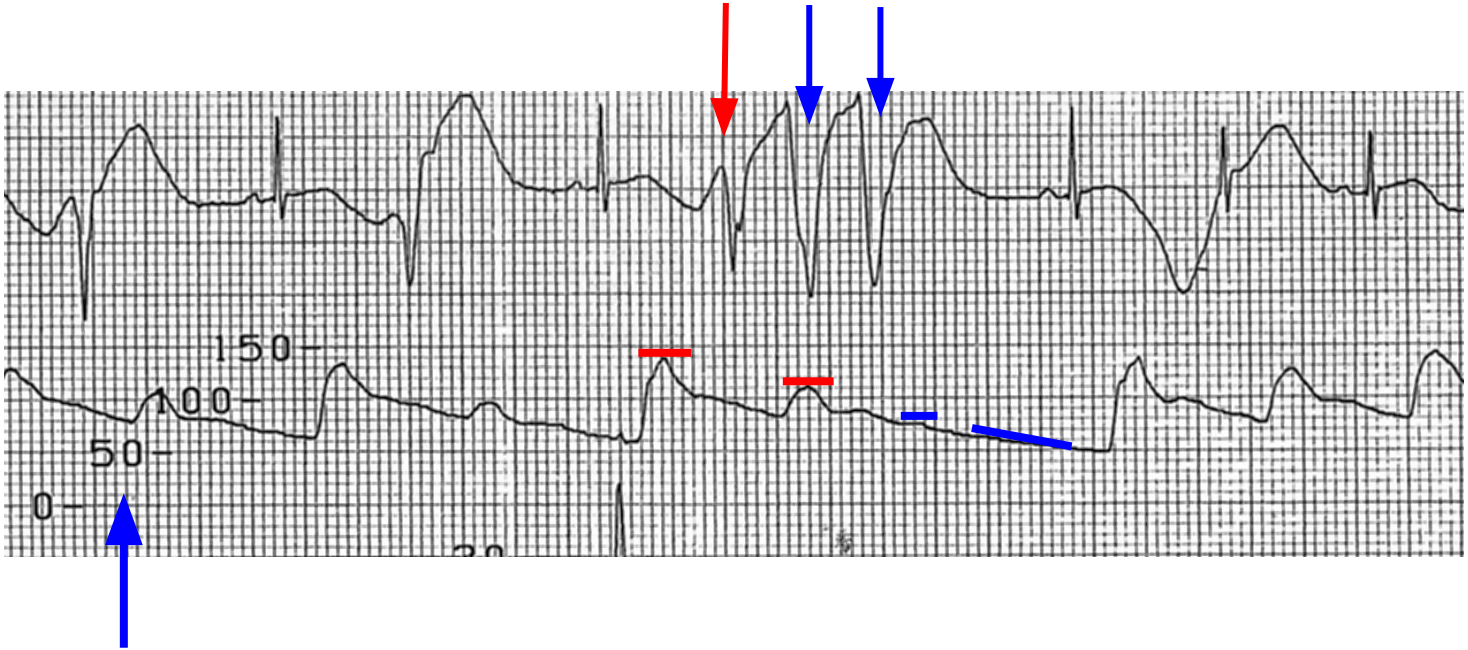
150
100
50
0

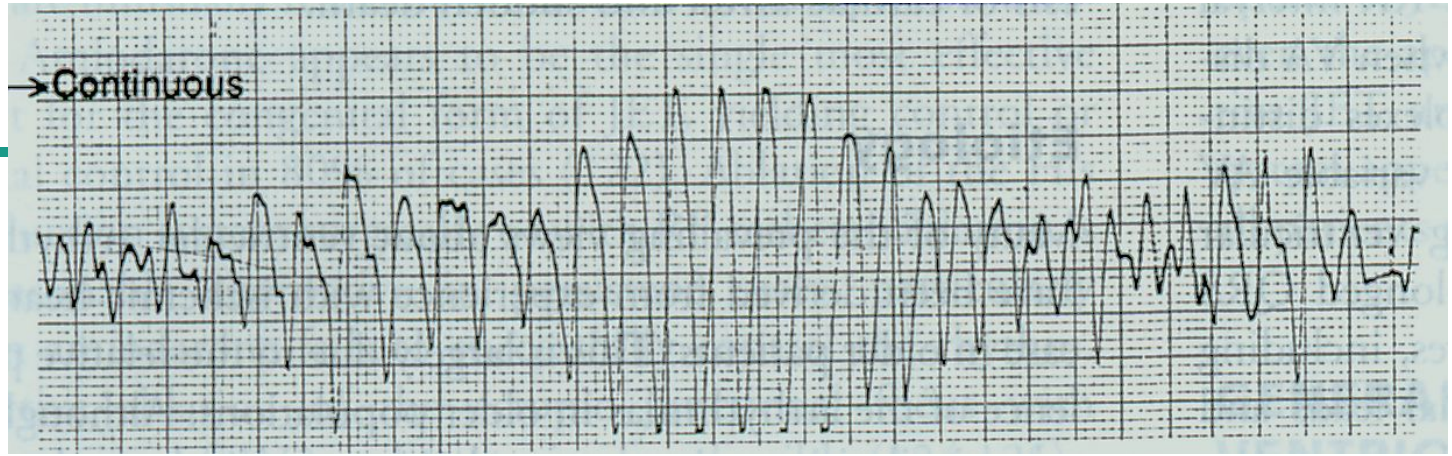
Continuous

That's Long QT, ARVD, Brugada, Catecholaminergic VT

The fast ventricular arrhythmias causing syncope without prodrome

Slower ventricular arrhythmias can cause palpitations and then syncope

What about Hypertrophic Cardiomyopathy?

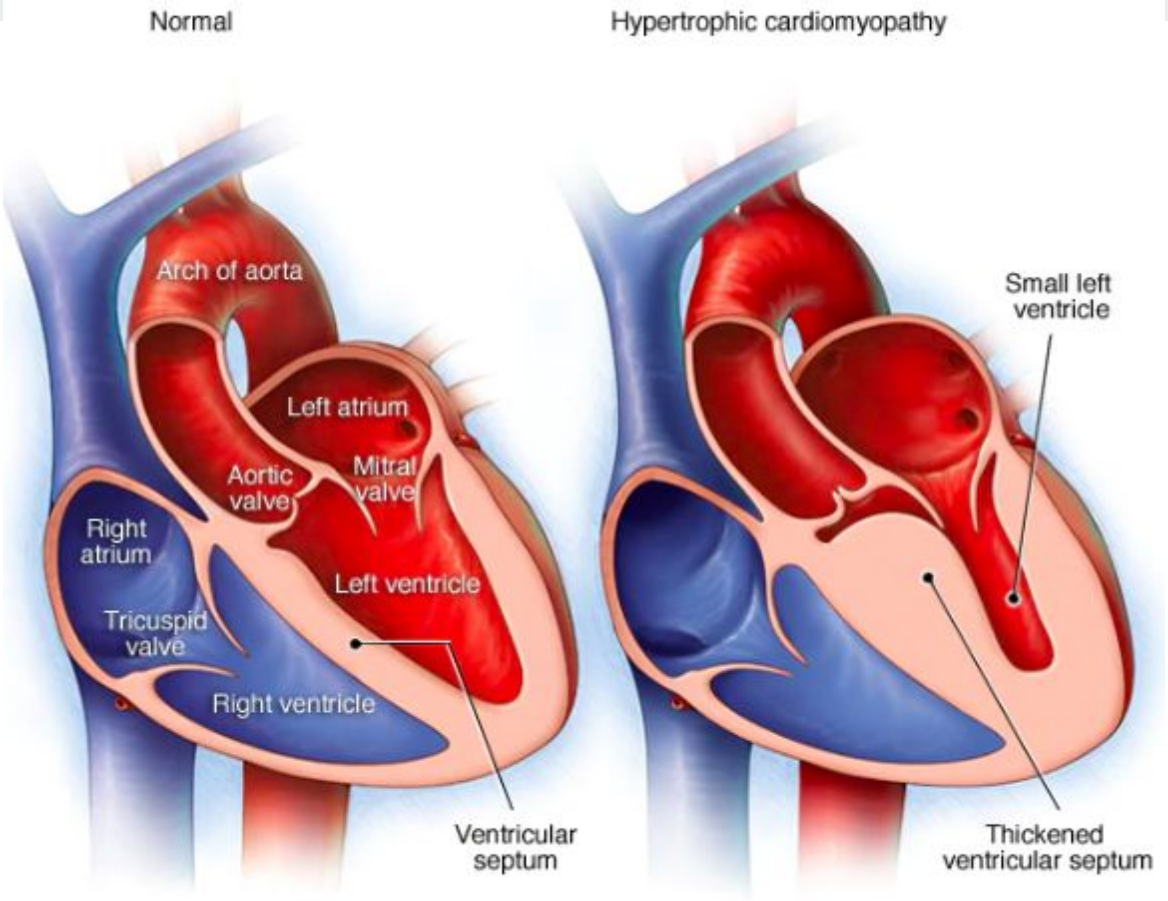

Hypertrophic cardiomyopathy

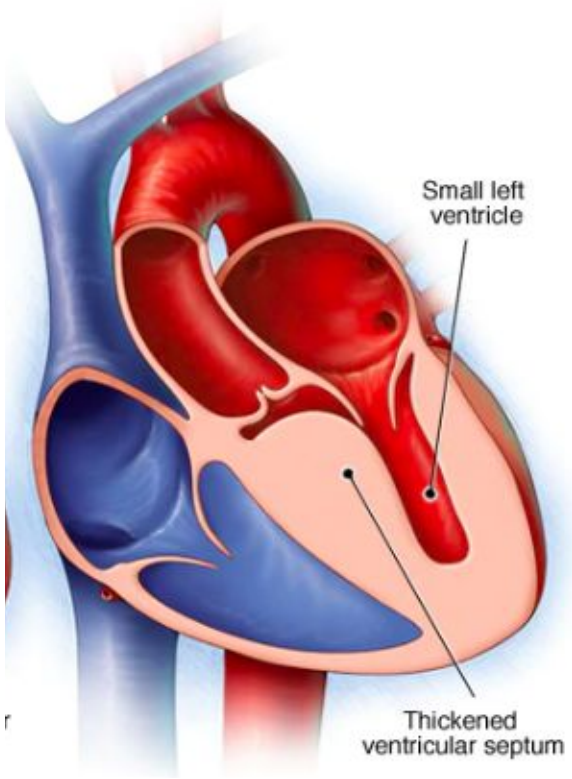

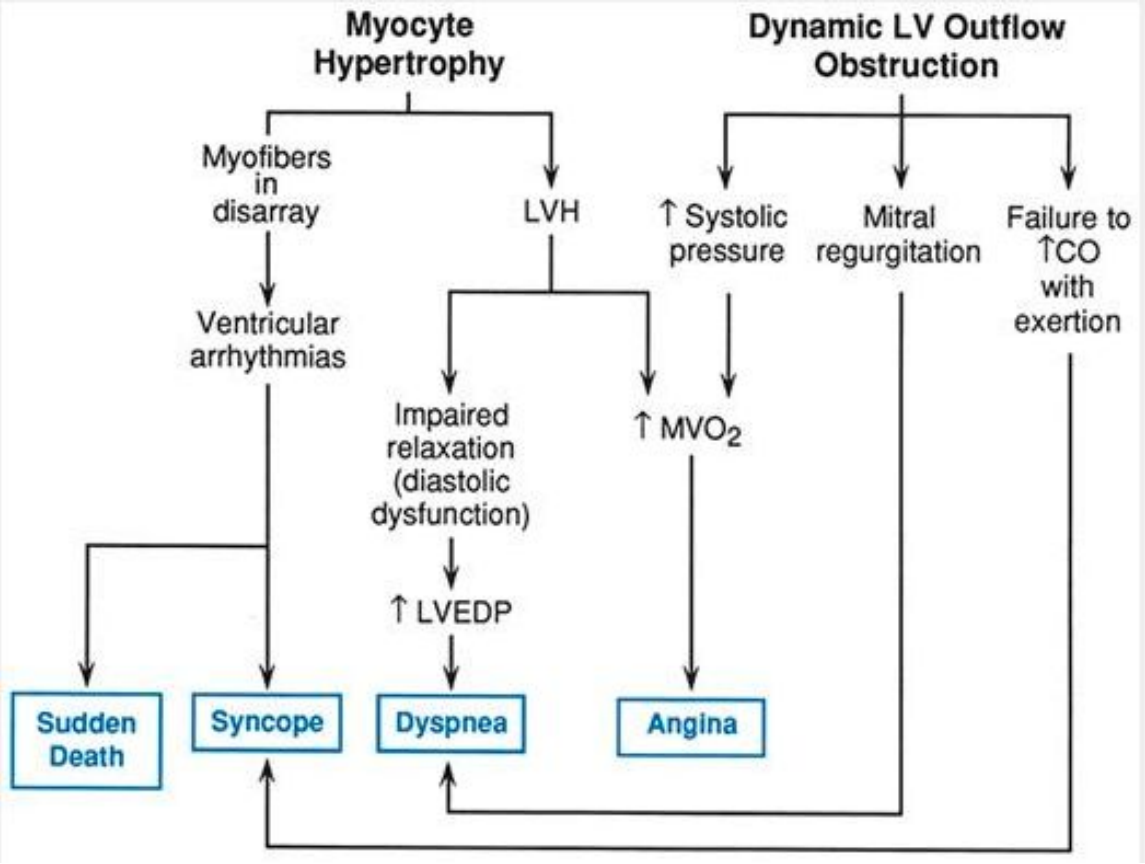

Table 1. Etiologies Of Syncope

Cardiac Causes	Noncardiac Causes
Structural • Hypertrophic cardiomyopathy • Anomalous coronary artery* • Myocarditis* • Pericarditis* • Valvular dysfunction* **Dysrhythmias** • Commotio cordis* • Long QT syndrome • Wolff-Parkinson-White syndrome • Supraventricular tachycardia • Brugada syndrome • Short QT syndrome* • Heart block • Sick sinus syndrome* • Arrythmogenic right ventricular dysplasia*	• Neurocardiogenic/vasovagal (most common) • Postural orthostatic tachycardia syndrome • Psychogenic pseudosyncope • Drugs and toxins* • Metabolic derangements, hypoglycemia • Breath-holding spells • Seizure • Trauma • Pregnancy • Pulmonary hypertension* • Pulmonary embolism*

Summary of concerning syncope events:

1. Syncope without warning
2. Syncope preceded by palpitations
3. Exertional syncope

Beyond Vasovagal Syncope

Cardiac syncope

POTS

--Postural Orthostatic Tachycardia Syndrome

What is Postural Orthostatic Tachycardia Syndrome?

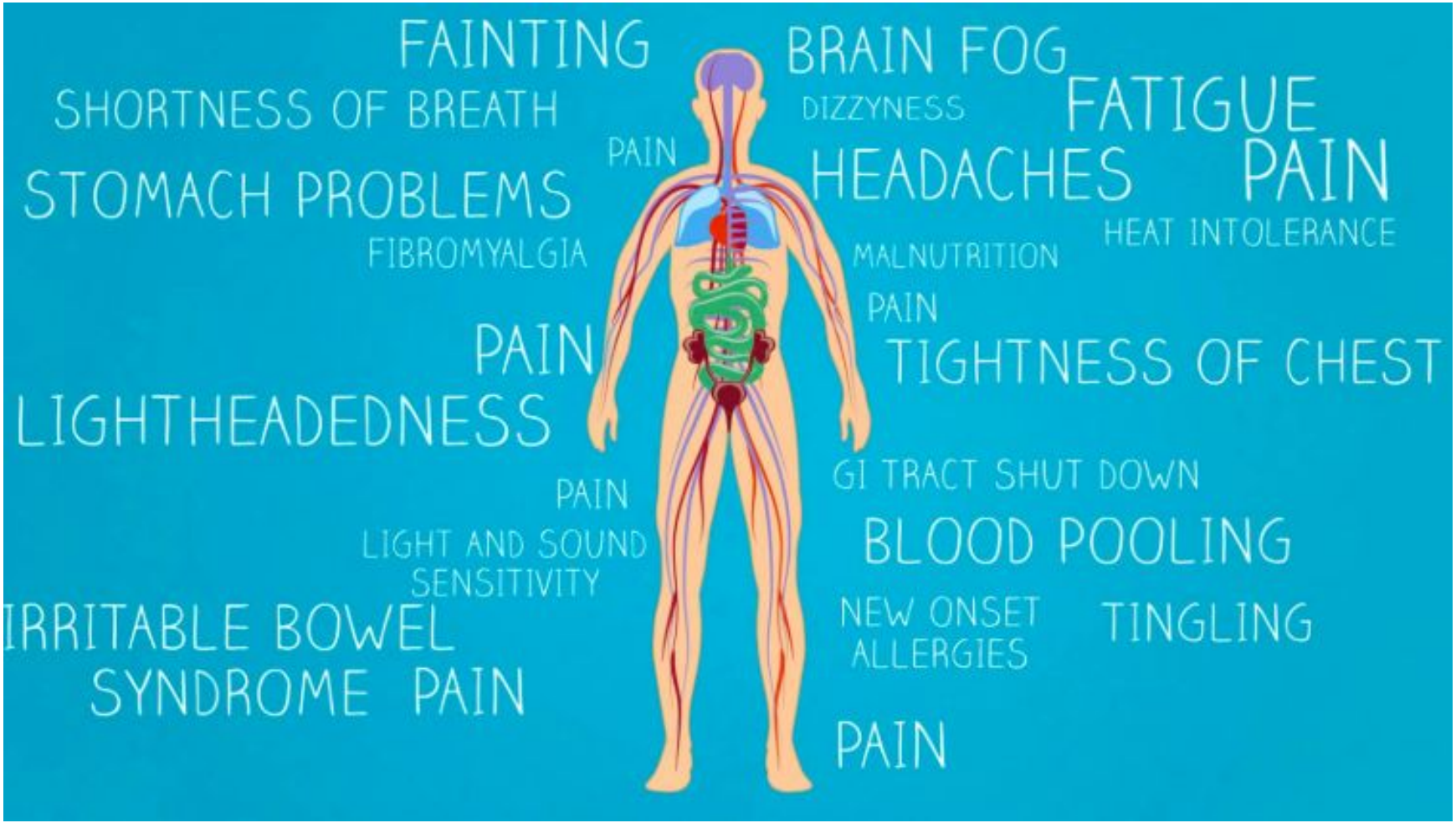

Dysautonomia International

Vasovagal syncope

"Aka"

- Neurocardiogenic syncope
- Orthostatic hypotension
- Postural hypotension
- Dysautonomia

Related: Postural Orthostatic Tachycardia Syndrome

Table 1. Etiologies Of Syncope

Cardiac Causes	Noncardiac Causes
Structural • Hypertrophic cardiomyopathy • Anomalous coronary artery* • Myocarditis* • Pericarditis* • Valvular dysfunction* **Dysrhythmias** • Commotio cordis* • Long QT syndrome • Wolff-Parkinson-White syndrome • Supraventricular tachycardia • Brugada syndrome • Short QT syndrome* • Heart block • Sick sinus syndrome* • Arrythmogenic right ventricular dysplasia*	• Neurocardiogenic/vasovagal (most common) • Postural orthostatic tachycardia syndrome • Psychogenic pseudosyncope • Drugs and toxins* • Metabolic derangements, hypoglycemia • Breath-holding spells • Seizure • Trauma • Pregnancy • Pulmonary hypertension* • Pulmonary embolism*

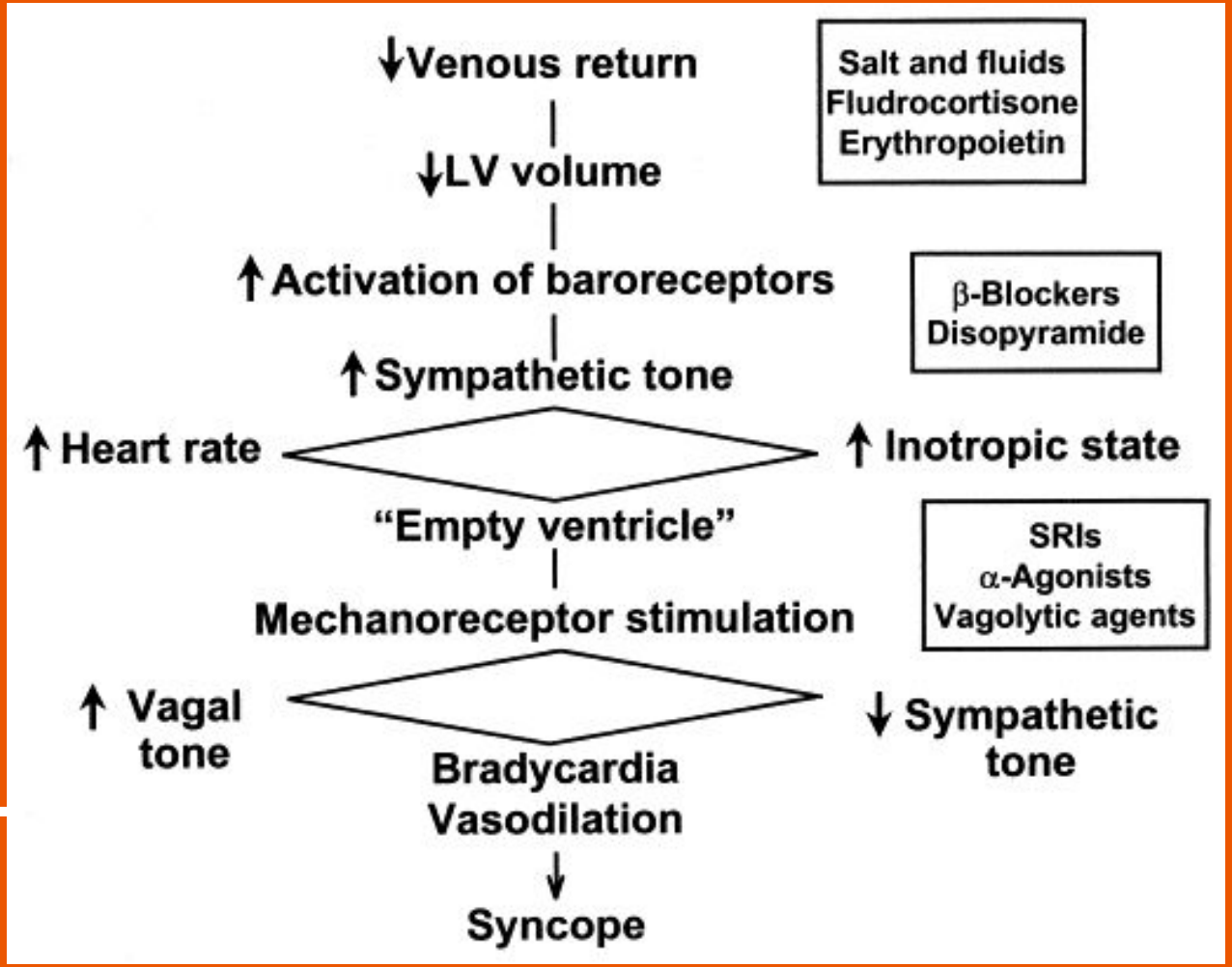
↓Venous return
Salt and fluids
Fludrocortisone
Erythropoietin
↓LV volume
↑Activation of baroreceptors
β-Blockers
Disopyramide
↑Sympathetic tone
↑Heart rate
↑Inotropic state
"Empty ventricle"
SRIs
α-Agonists
Vagolytic agents
Mechanoreceptor stimulation
↑ Vagal tone
↓ Sympathetic tone
Bradycardia
Vasodilation
Syncope

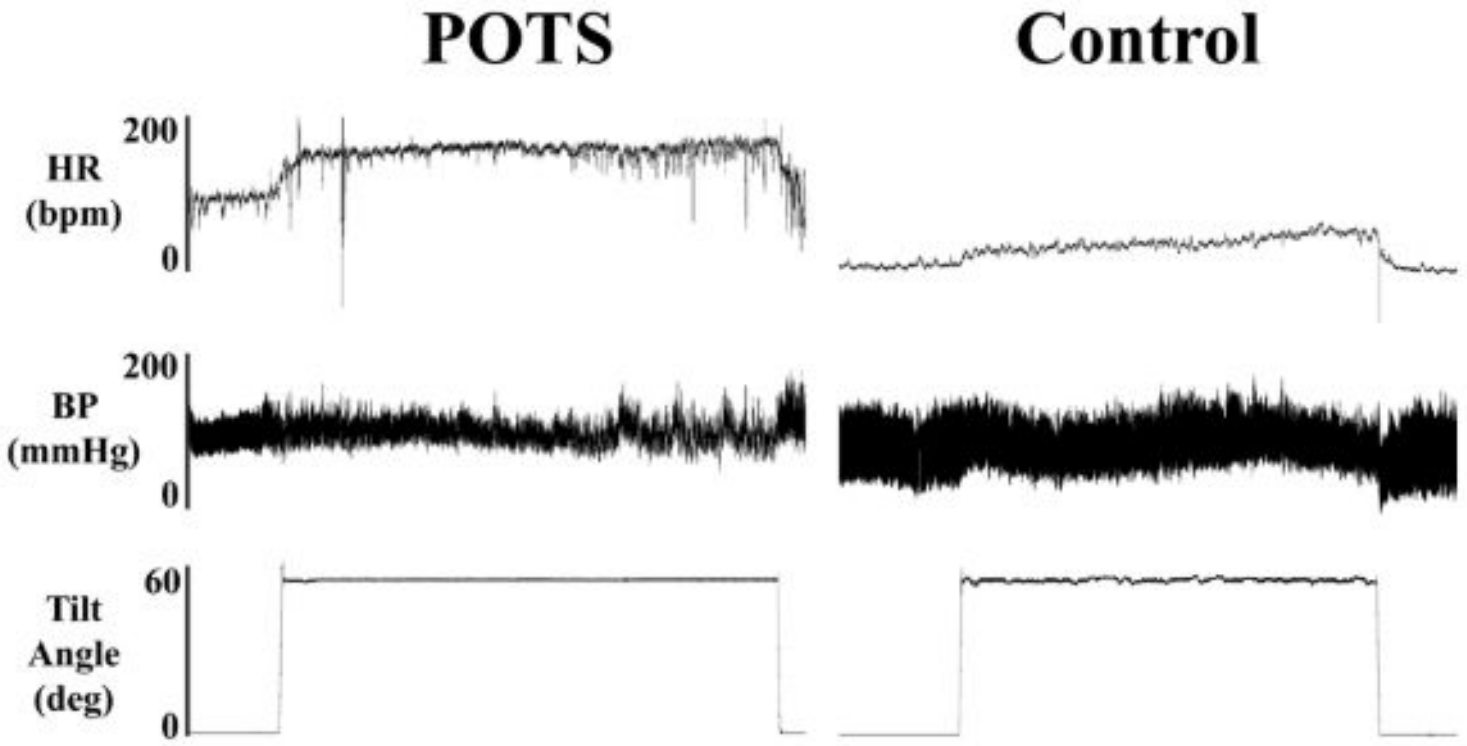

Heart rate (HR), blood pressure (BP), and tilt angle are shown for a POTS patient (left) and for a healthy subject (right) during a 30 minute head-up tilt test. Note the rapid and sustained increase in HR seen in POTS. Figure reprinted with permission from Raj SR et al., *Indian Pacing Electrophysiol. J.* 2006;6:84-99.[2]



Dysautonomia

Table. Diagnostic Criteria for Postural Orthostatic Tachycardia Syndrome

Sustained heart rate increase of 30 bpm or more (40 bpm in persons 12 to 19 years of age) within 10 minutes of standing or head-up tilt in the absence of orthostatic hypotension
Standing heart rate often is 120 bpm or more within 10 minutes of standing or head-up tilt
Orthostatic tachycardia may be accompanied by symptoms of cerebral hypoperfusion and autonomic overactivity that are relieved by decumbency
Criteria not applicable for low resting heart rate

AAFP 2012

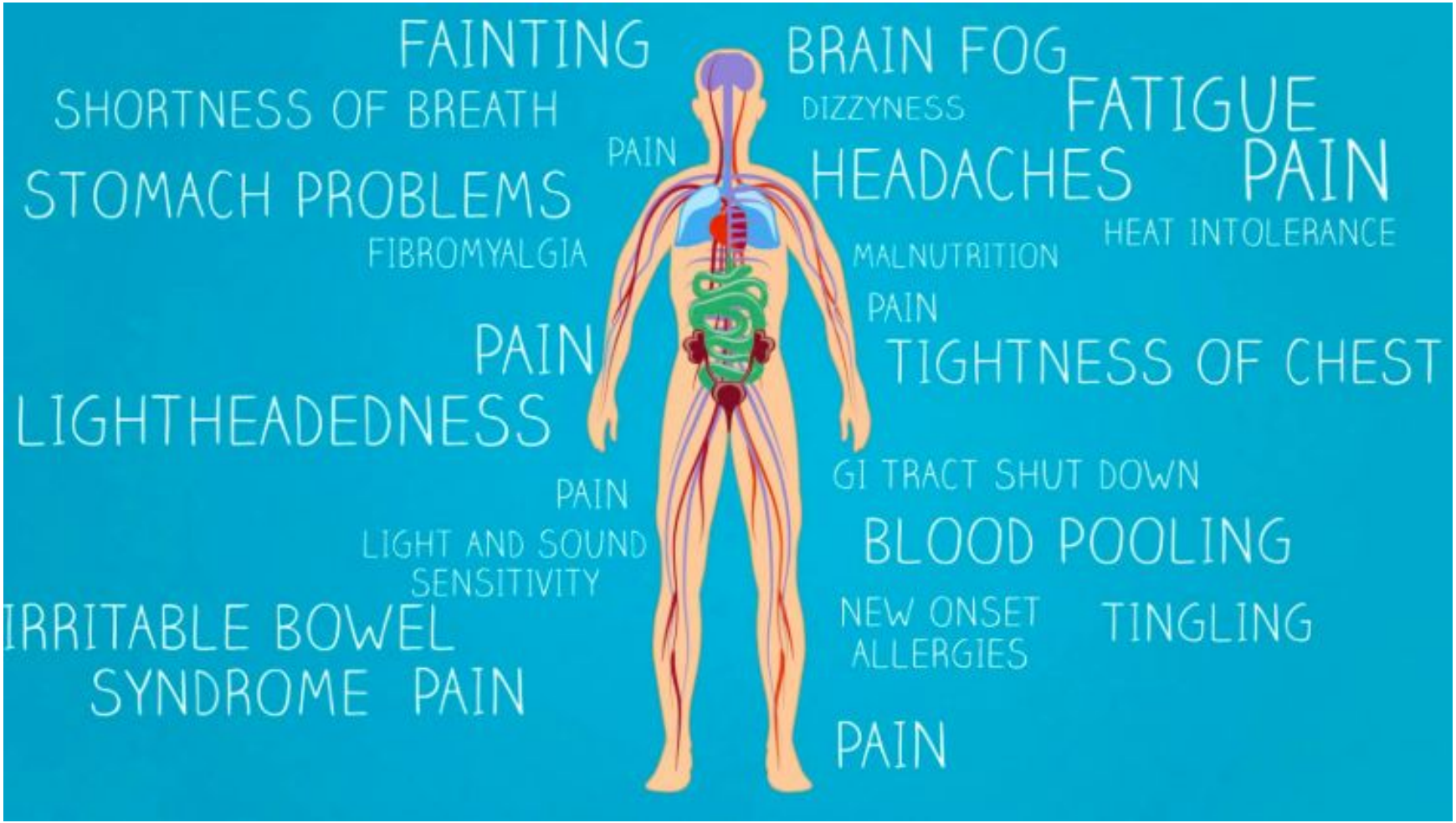

Dysautonomia International

POTS Treatment

- Exercise
- Increase fluid intake
- Salt
- Compression devices
- Muscle tensing
- Diet
- Routine

POTS treatment--medication

Beta blocker--heart rate control

Midodrine--alpha-1 antagonist

Fludrocortisone (Florinef)

Anti-depressants