Common Dermatologic Skin Conditions in Women

JACQUELINE DE LUCA, MD, FAAD
KAISER PERMANENTE DOWNEY

1

Disclosure

- I have no conflicts of interest or financial relationships to disclose
- Some medications discussed may be used off-label

2

Overview

- Dermatoses in pregnancy
- Candida Treatment
- Molluscum Contagiousum
- Hidradenitis Suppurativa

3

Dermatoses in Pregnancy

- Physiologic changes
- Pre-existing dermatoses affected by pregnancy
- Dermatoses specific to pregnancy

4

Physiologic skin changes in pregnancy	
Pigmentation	
Hyperpigmentation (*diffuse with accentuation of areolae mammae and linea nigra*)	Increased hormone levels (estrogen, progesterone, MSH) lead to hyperpigmentation (by up to 90% of pregnant women) and melasma (70%).
Melasma	Aggravating factors: dark skin, UV exposition.
Connective tissue	
Striae distensae	Occur in up to 90% of patients, probably combined effects of genetic predisposition, abdominal distension and hormonal factors.
Vascular system	
Edema	Weight gain, redistribution of volume and hormonal factors lead to edema and varicosities and to formation of new vessels. Main manifestation in the third trimester, usually reversible after delivery.
Varicosities/hemorrhoids	
Spider angiomas, teleangiectasia	
Palmar erythema	
Gingiva hyperemia and hyperplasia	
Pyogenic granuloma	
Glandular function	
Increased eccrine gland function (*except palms*)	Increased incidence of milaria, hyperhidrosis and dyshidrotic eczema on the one hand and improvement of hidradenitis suppurativa on the other. Data on sebaceous gland activity (increased?) contradictory.
Decreased apocrine gland function	
Disturbed sebaceous gland function (*acne gravidarum, Montgomery glands*)	
Hair	
Hypertrichosis	Prolongation of anagen phase leads to hypertrichosis during pregnancy, synchronized transition into the telogen phase later to postpartal effluvium. Normalization within 6~12 months.
Postpartal telogen effluvium	
Postpartal androgenetic alopecia (*rare; typically "male-pattern"*)	
Nails	
Increased brittleness	Entirely unspecific and reversible.
Distal onycholysis	
Subungual hyperkeratoses	
Transverse grooving	

5

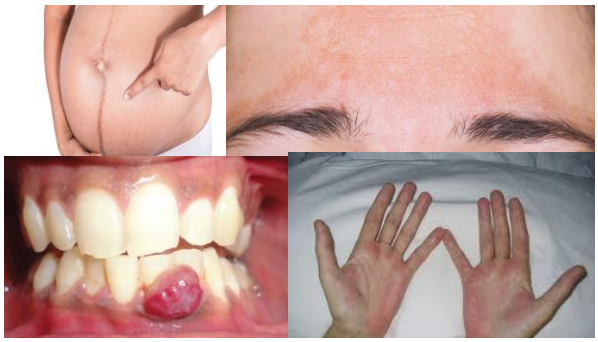

6

Dermatoses in pregnancy

- Pemphigoid gestationis
- Polymorphic eruption of pregnancy (PEP) or pruritic urticarial papules and plaques of pregnancy (PUPPP)
- Atopic eruption of pregnancy
- Intrahepatic cholestasis of pregnancy
- Pustular psoriasis of pregnancy

7

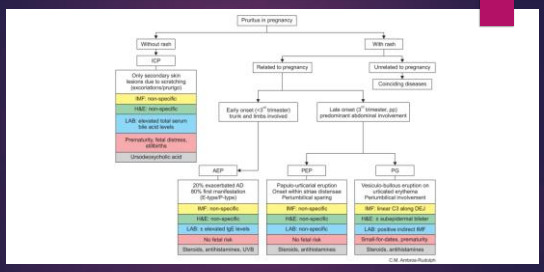

8

Pemphigoid gestationis (herpes gestationis)

- second or third trimester
- IgG1 autoantibodies directed against the 180 kilodalton bullous pemphigoid antigen (BP180 or collagen XVII); hemidesmosomal protein
- antibodies bind not only to the basement membrane zone of the epidermis, but also to that of chorionic and amniotic epithelia→mom and sometimes baby too can have blisters

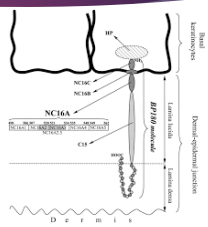

9

Pemphigoid gestationis

- Start as urticarial plaques or papules +/- vesicles surrounding the umbilicus
- Spreads to trunk and extremities→ tense bullae and vesicles
- mucous membranes are usually spared
- flare-ups at delivery (75%)
- resolves then within weeks to months
- may recur with menstruation and hormonal contraception
- **Recurs** with subsequent pregnancies and is usually **more severe**
- Newborn complications: **small-for-date and premature babies**
  - Only 10% of newborns develop mild skin lesions; resolve spontaneously within days to weeks (neonatal pemphigoid

10

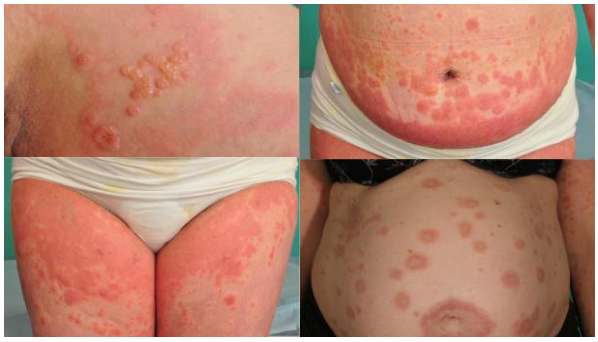

11

Pemphigoid gestationis: diagnosis

- clinical evaluation, histological findings, direct immunofluorescence (DIF) or indirect immunofluorescence (IIF), enzyme-linked immunosorbent assay (ELISA)
- **Pathology**
  - subepidermal vesicle with a perivascular lymphocytic and eosinophilic infiltrate
  - Eosinophils at DEJ

12

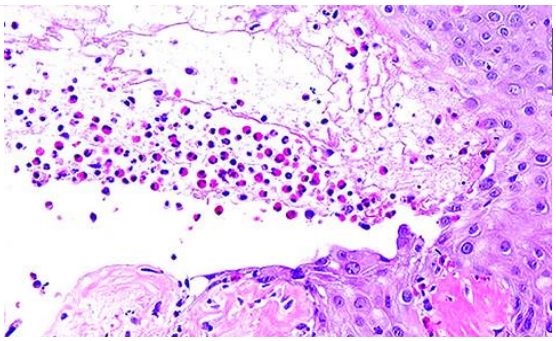

13

Pemphigoid gestationis: diagnosis

- **Direct immunofluorescence (DIF)**
  - perilesional skin biopsy->homogeneous, linear deposit of complement C3 at the basement membrane zone
- **Laboratory tests**
  - ELISA BP180 NC16A : Antibodies against the noncollagenous extracellular domain of BP180 known as NC16A (same site as bullous pemphigoid)
    - sensitivity and specificity of BP180 NC16A ELISA test range from 96 to 100 percent
    - levels of circulating anti-BP180 antibodies correlate with the disease severity→can use to monitor the response to treatment

14

DIF

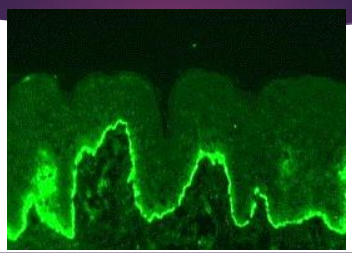

15

Pemphigoid gestationis: Treatment

- localized disease→high-potency topical corticosteroids
- Severe/symptomatic disease→systemic corticosteroids
  - prednisone 0.5 mg/kg per day during pregnancy
    - Treatment with systemic corticosteroids was not found to be a factor in increasing or decreasing fetal risks in PG
    - Taper dose once blister formation is stopped, though may need to increase taper if flare with delivery
  - Prednisone 2 mg/kg per day postpartum if severe
- Pruritus→chlorpheniramine, loratadine and cetirizine
- Patients have an increased risk of other autoimmune diseases (graves)

16

Polymorphic eruption of pregnancy (PEP), aka pruritic urticarial papules and plaques of pregnancy (PUPPP),

- Common, benign, self-limiting pruritic inflammatory disorder
  - approximately 1 in 160 to 300 pregnancies
- nulliparous women in the last few weeks of pregnancy or immediately postpartum
  - degree of stretching of the abdominal skin may play a role→more common with multiple gestation
  - mean onset 35 weeks

17

Polymorphic eruption of pregnancy (PEP)

- erythematous papules and plaques within striae (usually abdominal) and spread to the extremities, chest, and back
  - pale halo
  - Extremely pruritic
  - ½ patients develop more polymorphic lesions (targetoid, erythematous patches, vesicles
- lasts four to six weeks and resolves within two weeks postpartum

18

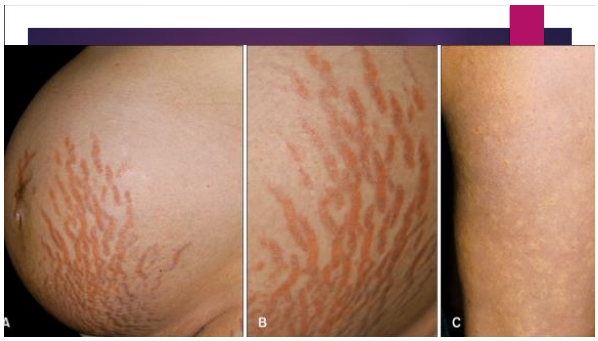

19

PEP: diagnosis

- **Clinical diagnosis**
- Pathology
  - perivascular (superficial and deep) and interstitial lymphocytic infiltrate containing eosinophils

20

PEP: Treatment

- Symptomatic treatment
- topical corticosteroids
- Antihistamines
- PEP poses no increased risk of fetal or maternal morbidity
- Recurrence is rare

21

Atopic eruption of pregnancy (AEP)

- Most common of the pregnancy dermatoses (> 50% cases)
- Starts during early pregnancy
  - 75% < 3rd trimester
- Associated with a personal or family history of atopy (seasonal rhinitis, asthma, and/or atopic dermatitis)
  - most cases the first manifestation of atopic skin changes (~80%)
- Occurs 2/2 enhancement of Th2 cytokine production during pregnancy

22

AEP: clinical features

- **E- type AEP: Eczema →**face, neck, and flexural areas, similar to classic atopic dermatitis; xerosis
- **P- type AEP: Prurigo of pregnancy→**erythematous, excoriated nodules or papules on the extensor surfaces of the limbs and trunk
- **Pruritic folliculitis of pregnancy→**follicular papulopustular eruption (rare)

23

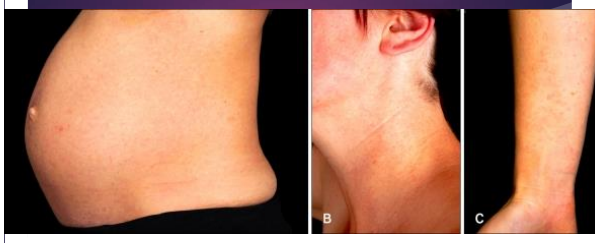

24

AEP: diagnosis

- Clinical diagnosis
- **Pathology** — Spongiosis and a perivascular mononuclear infiltrate are common features of eczematous eruptions
- Only biopsy to r/o pemphigoid gestationis

25

AEP: treatment

- Symptomatic
- Emollients
- Low- to mid-potency topical corticosteroids
- Antihistamine
- Phototherapy: UVB
- No adverse effects on the fetus
- AEP may recur with subsequent pregnancies

26

Intrahepatic cholestasis of pregnancy

- Late pregnancy
- Mutation encoding ABCB4 gene encoding transport proteins necessary for bile excretion
- Hep C infection
- Severe generalized pruritus, worst on palms and soles
- No primary skin lesions
- +/- jaundice (20-30%)

27

Intrahepatic cholestasis of pregnancy: diagnosis

- **Total serum bile acid levels >11 mmol/L**
- Elevated alkaline phosphatase levels
- +/- elevated bilirubin levels, ALT, AST

28

ICP: Treatment

- oral antihistamines for pruritus
- ursodeoxycholic acid (ursodiol)→improve cholestasis and reduce adverse fetal outcomes
  - Recommended dosing: 15 mg/kg/day
- Cholestasis and jaundice→vitamin K deficiency and coagulopathy.
- Risk for gall stones and **intra/postpartum hemorrhage**
- Elevated serum bile acids secondary to decreased excretion→abnormal uterine contractions, vasoconstriction of chorionic veins and cross the placenta and cause impaired fetal heart function
- Will recur in subsequent pregnancies
- Increased risk of prematurity (19-60%), intrapartal fetal distress (22-33%), and stillbirths (1-2%)

29

Pustular psoriasis of pregnancy (PPP); aka impetigo herpetiformis

- Rare variant of generalized pustular psoriasis
- Presents during the 3rd trimester
- symmetric, erythematous plaques studded at the periphery with sterile pustules in a circinate pattern
- plaques enlarge from the periphery as the center becomes eroded and crusted
- Begins in the flexural areas and spreads centrifugally
- Onycholysis
- Oral erosions
- Hands, feet, and face are usually spared
- Flu like symptoms: malaise, fever, anorexia, nausea, vomiting, diarrhea, tachycardia, LAD, and seizures

30

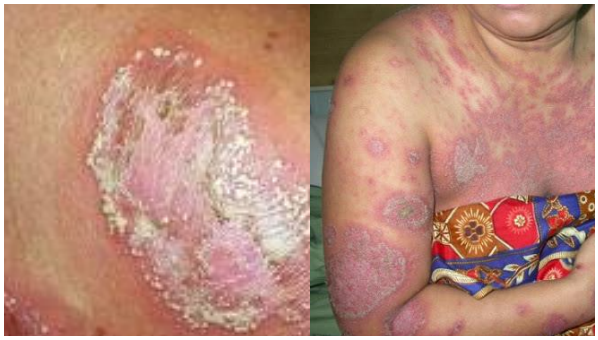

31

Pustular psoriasis of pregnancy (PPP)

- **Pathology**
  - same as pustular psoriasis
  - Spongiform pustules with neutrophils are observed in the epidermis. Psoriasiform hyperplasia and parakeratosis also occur
- **Labs**
  - Hypocalcemia
  - Electrolyte abnormalities
  - Hypoalbuminemia
  - liver and renal dysfunction
  - Leukocytosis
  - Culture for superinfection

32

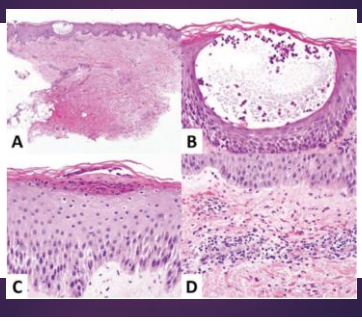

33

Pustular psoriasis of pregnancy

- Topical and systemic steroids: 30-60 mg prednisone/day
- Treat secondary infections, hypocalcemia, electrolyte abnormalities
- Unresponsive cases →cyclosporine, NBUVB, or induction of early delivery
- postpartum period, oral retinoid can be given
- recurrence in subsequent pregnancies->earlier and more severe→worse maternal-fetal prognosis
- placental insufficiency, premature rupture of membranes, preterm labor and intrauterine growth restriction→ stillbirth, neonatal death, or fetal abnormalities

34

Recurrent candidiasis

- oropharyngeal involvement or vaginitis result from changes in the normal flora
- older adults who wear dentures; patients treated with antibiotics, chemotherapy, xerostomia, inhaled glucocorticoids or radiation therapy
- cellular immune deficiency states, such as AIDS
- potassium hydroxide (KOH) preparation on the scrapings→budding yeasts with or without pseudohyphae are seen

35

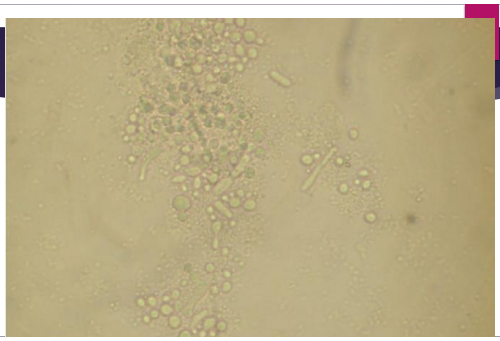

36

Candida vulvovaginitis

- oral fluconazole
  - maintains therapeutic concentrations in vaginal secretions >72 hours after the ingestion of a single 150 mg tablet
  - interactions are rare at the dose used to treat vulvovaginal candidiasis
- topical imidazole (clotrimazole/miconazole) vaginally for seven days

37

Candida vulvovaginitis

- Oral vs topical?
  - oral and topical antimycotic drugs achieved comparable clinical cure rates, >90 %
  - topical treatments have fewer side effects
  - oral medication may cause GI SE, headache, rash, and transient liver function abnormalities
  - oral medications take longer to relieve symptoms

38

Recurrent treatment

- Fluconazole150 mg every 72 hours for three doses, followed by maintenance fluconazole therapy once per week for six months
- Treat each recurrent episode as an episode of uncomplicated infection
- Treat each recurrent episode with longer duration of therapy
- The Infectious Diseases Society of America (IDSA) recommends 10 to 14 days of induction therapy with a topical or oral azole, followed by diflucan150 mg once per week for six months

39

Suppressive therapy

- Fluconzaole150 mg orally once per week for six months

40

Molluscum Contagiousum

- Molluscum contagiosum virus (MCV) is a double-stranded DNA virus and member of the poxvirus family
- MCV is spread by direct skin-to-skin contact which can be sexual, non-sexual, or autoinoculation
- incubation period of the virus vary from one week to six months, but it is typically between two and six weeks
- firm rounded papules, pink or skin-colored, with a shiny and umbilicated surface
- self-limited (resolve in 6–9 months); rare cases >4 years
  - "beginning of the end" (BOTE) sign
- occurs in healthy adolescents and adults
  - sexually transmitted disease
  - participation in contact sports
- atopic dermatitis?
- more severe disease (widespread or giant mollosucum) with inherited immunodeficiencies, during HIV infection, or following treatment with immunosuppressive drugs.

41

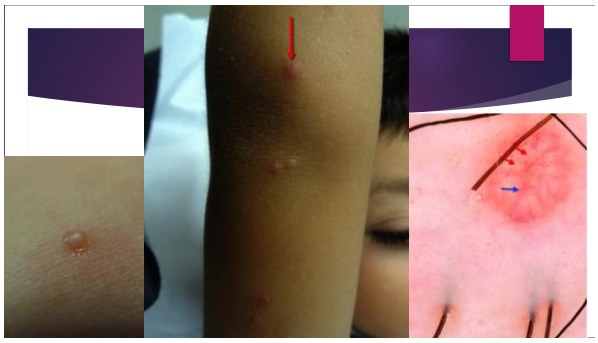

42

MC: treatment

- Active treatment (mechanical, chemical, immunomodulatory, and antiviral) in patients with MC is controversial
- self-limited course of infection
- lack of evidence to define the best therapy
- treatment can be time consuming, cause pain, irritation, dyspigmentation, or scarring
- But all patients should:
  - not to scratch or rub the lesions
  - not share towels, tub, or bath utensils

43

Presentations of molluscum

- **Molluscum dermatitis:** eczematous patches or plaques surrounding MC lesion
- **Inflamed lesions:** erythema and swelling of individual lesions, BOTE sign
- **Gianotti-Crosti syndrome**: pruritic erythematous papules on the face, buttocks, and extremities are common sites for lesion development→faster resolution

44

Pathology

- keratinocytes containing eosinophilic cytoplasmic inclusion bodies (also known as molluscum bodies or Henderson-Paterson bodies)

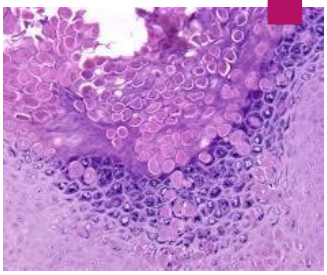

45

Treatment

- sexually-transmitted molluscum contagiosum
- immunocompromised individuals
- For healthy children decision to treat requires a conversation

46

Treatment

- **Cryotherapy**
  - rapidly effective therapy in a randomized trial
  - Pain, scarring and temporary or permanent hypopigmentation
- **Curettage**
  - physical removal of the molluscum contagiosum lesion with a curette
  - 40-80% efficacy
  - discomfort and minor bleeding
  - small, depressed scars
  - Other methods are forceps, scalpel, comedone extractor

47

Treatment

- **Cantharidin**
- Apply with wooden tip of cotton swab→development of a small blister; need to wash off 2-6 hours after treatment
- 30-90% efficacy
- apply a bandage to cover treatment areas
- Treatments can be repeated every two to four weeks until all lesions have resolved
- burning, pain, erythema, and pruritus
- Post-inflammatory dyspigmentation, scarring

48

Treatment

- **Podophyllotoxin** (Condylox)
  - antimitotic agent twice daily for three consecutive days per week for up to four weeks
  - 0.5% podophyllotoxin was 92% cure rate
  - Local erythema, burning, pruritus, inflammation, and erosions can occur with the use of this agent
  - Don't use in children

49

Treatment

- **Imiquimod**
- has **not** been proven more effective than placebo in randomized trials
- Erythema and pruritus at application sites
- Flu-like symptoms may also occur

50

Treatment

- **Potassium hydroxide** (5 or 10%)
- three times per week to twice daily
- once-daily application of 10% KOH, 15% KOH, or placebo until complete clearance or a maximum of 60 days→clearance in 59, 64, and 19 percent, respectively)
- stinging and burning at the site of application (worse with higher concentration)
- dyspigmentation

51

Treatment

- **Salicylic acid**
- keratolytic
- **Topical retinoids:**
- Tretinoin (0.5% cream, 0.1% cream, or 0.025% gel), adapalene, and tazarotene→local irritation that damages the viral protein-lipid
- Irritation and xerosis are expected side effects.

52

Hidradenitis Suppurativa

- chronic inflammatory condition that affects skin regions bearing apocrine glands
- Occurs after puberty
- 3 x more common in women
- Genetic; 1/3 cases have FH
- Smoking and obesity are major risk factors

53

Hidradenitis suppurativa

- noninflamed or inflamed nodules
- sinuses that may be draining or non-draining
- abscesses in anogenital, inguinal and/or axillary regions
- superinfection (staph aureus) is associated with severity of symptoms.

54

Hurley Staging System

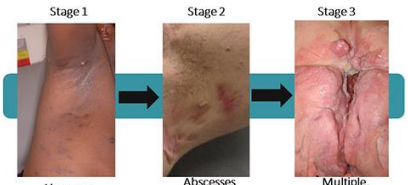

Abscesses
No sinus tracts

Abscesses
Sinus tracts
Scarring

Multiple,
interconnected tracts
and abscesses

- Limitation: assesses only severity of skin condition, not disease activity

Images courtesy of Alexa B. Kimball, MD.
Kimball AB, et al. *Brit J Derm*. 2014;171:1434-1442.

55

HURLEY - I	HURLEY - II	HURLEY - III or REFRACTORY
LOCALIZED *First line:* Topical (Clindamycin and Benzyl peroxide) *Second line:* Doxycycline *Third line:* Nd:YAG *Refractory:* Surgical intervention **GENERALIZED** *First line:* Topical (Clindamycin and Benzyl peroxide) Systemic antibiotics (if needed) *Second line:* Nd:YAG	*First line:* Systemic antibiotics (rifampin + clindamycin). Nd:YAG (if needed) *Refractory:* Anti-TNF therapy (adalimumab/infliimab). Intravenous carbapenem antibiotic *Second line:* Systemic antibiotics. Alternatively, localized surgical deroofing or laser excision.	Treatment with previous options based on need. Refractory: Laser excision repair, radiotherapy or reconstructive surgery.

56

HS: Treatment

- topical therapy
  - Clindamycin solution, Hibiclens wash, BPO wash/gel, bleach baths
- Oral antibiotics
  - Doxycycline 100 mg BID
  - clindamycin 300 mg BID and rifampicin 300 mg BID
- IL Kenalog

57

HS: non-pharmacologic options

- weight loss
- vitamin B12
- vitamin D
- zinc supplementation
- dietary avoidance of brewer's yeast

58

HS: Treatment

- Antiandrogens
  - ethinyl estradiol +/- cyproterone
  - finasteride 5 mg/day
  - Spironolactone
  - metformin
- Isotretinoin
  - Only improved lesions in 1/4 of participants, most of whom had mild condition→not favored treatment

59

HS: Treatment

- Anakinra (inhibits binding of IL-1 to its receptor)
- Infliximab (TNF-alpha inhibitor)
- Etanercept (TNF-alpha inhibitor)
- Apremilast (phosphodiesterase-4 inhibitor)
- Secukinumab (interleukin-17A antibody)

60

HS: Treatment

- Surgical management
  - Incision and drainage of acute abscesses
  - Curettage and deroofing of nodules, abscesses and sinuses
  - Laser ablation of nodules, abscesses and sinuses
  - Wide local excision of persistent nodules
  - Radical excisional surgery of entire affected area
  - Nd: YAG laser hair removal

61

HS: adalimumab

- U.S. Food and Drug Administration (FDA) approved the first treatment for HS in 2015
- Reserved for adults who have moderate (Hurley stage II) or severe (Hurley stage III) HS
- Initial dose (Day 1): 160 mg
- Second dose two weeks later (Day 15): 80 mg
- Third (Day 29) and subsequent doses: 40 mg every week

62

Adalimumab

- Primary endpoint was HiSCR at week 12, defined as at least a 50% reduction from baseline in abscess and inflammatory nodule count, with no increase in abscess and draining-fistula counts

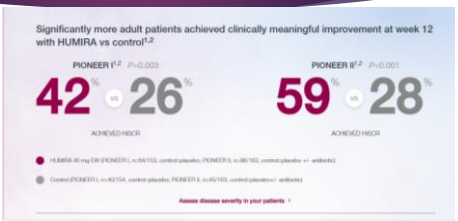

63

References

Shimanovich I, Bröcker EB, Zillikens D. Pemphigoid gestationis: new insights into the pathogenesis lead to novel diagnostic tools. BJOG. 2002 Sep;109(9):970-6.

BB Yap. Impetigo herpetiformis: A case report and review of literature. Egyptian Dermatology Online Journal 4 (1): 4, June, 2008.

Ambros-Rudolph CM. Dermatoses of pregnancy - clues to diagnosis, fetal risk and therapy. Ann Dermatol. 2011 Aug;23(3):265-75.

Sävervall C, Sand FL, Thomsen SF. Pemphigoid gestationis: current perspectives. Clin Cosmet Investig Dermatol. 2017 Nov 8;10:441-449.

Rodrigo Meza-Romero, Cristián Navarrete-Dechent, and Camila Downey. Molluscum contagiosum: an update and review of new perspectives in etiology, diagnosis, and treatment Clin Cosmet Investig Dermatol 2019; 12: 373–381

Agrawal A, Sharma YK. Hidradenitis suppurativa: A systematic review and meta-analysis of therapeutic interventions. Indian J Dermatol Venereol Leprol. 2019 Nov-Dec;85(6):617.

64

Questions?

65