Embolization techniques in trauma and bleeding

Roger Tomihama, M.D.
Assistant Professor of Radiology
Loma Linda University Medical Center
Department of Radiology
Section of Vascular and Interventional Radiology

Disclosures

- None

Learning objectives

- Current concepts and management of pelvic trauma
- Unusual case of penetrating trauma
- Atypical management of GI bleeding

Pelvic trauma

- Trauma surgeon's perspective and expectations
- VIR response times
- Role of nonselective internal iliac artery embolization

Trauma page comes in for angio…

- What are we thinking?

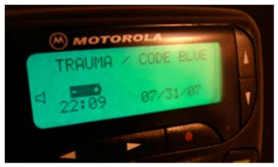

Trauma page comes in for angio…

- What are we thinking?
  - Hemodynamically stable?
  - Active contrast extravasation on CT?
  - Transfusion requirements?
  - Is the patient going to the OR?
  - Other injuries?

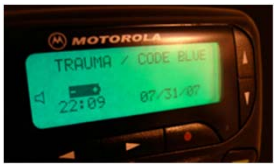

Trauma page comes in for angio…

- What are we thinking?
  - Hemodynamically stable?
  - Active contrast extravasation on CT?
  - Transfusion requirements?
  - Is the patient going to the OR?
  - Other injuries?
- However, what are our trauma surgeon thinking?



Trauma surgeon's perspective

- In 2001, the Eastern Association for the Surgery of Trauma (EAST) published practice management guidelines for the management of hemorrhage in pelvic trauma.
  - Updated in 2011
  - Which patients require emergent pelvic angiography?

Trauma surgeon's perspective

- Based on the literature and consensus agreement, these indications were deemed appropriate for emergent pelvic angiography?

Trauma surgeon's perspective

- Based on the literature and consensus agreement, these indications were deemed appropriate for emergent pelvic angiography?
  - Pelvic fractures with hemodynamic instability or ongoing bleeding without other sources. (level 1 evidence)

Trauma surgeon's perspective

- Based on the literature and consensus agreement, these indications were deemed appropriate for emergent pelvic angiography?
  - Pelvic fractures with hemodynamic instability or ongoing bleeding without other sources. (level 1 evidence)
  - Pelvic arterial contrast extravasation on CT regardless of hemodynamic status. (level 1 evidence)

Trauma surgeon's perspective

- Based on the literature and consensus agreement, these indications were deemed appropriate for emergent pelvic angiography?
  - Pelvic fractures with hemodynamic instability or ongoing bleeding without other sources. (level 1 evidence)
  - Pelvic arterial contrast extravasation on CT regardless of hemodynamic status. (level 1 evidence)
  - Patients with ongoing bleeding after pelvic angiography (+/- embolization) without other sources. (level 2 evidence)

Trauma surgeon's perspective

- Based on the literature and consensus agreement, these indications were deemed appropriate for emergent pelvic angiography?
  - Pelvic fractures with hemodynamic instability or ongoing bleeding without other sources. (level 1 evidence)
  - Pelvic arterial contrast extravasation on CT regardless of hemodynamic status. (level 1 evidence)
  - Patients with ongoing bleeding after pelvic angiography (+/- embolization) without other sources. (level 2 evidence)
  - Age > 60 years with major pelvic fracture regardless of hemodynamic status. (level 2 evidence)

Trauma surgeon's perspective

- Based on the literature and consensus agreement, these indications were deemed appropriate for emergent pelvic angiography?
  - Pelvic fractures with hemodynamic instability or ongoing bleeding without other sources. (level 1 evidence)
  - Pelvic arterial contrast extravasation on CT regardless of hemodynamic status. (level 1 evidence)
  - Patients with ongoing bleeding after pelvic angiography (+/- embolization) without other sources. (level 2 evidence)
  - Age > 60 years with major pelvic fracture regardless of hemodynamic status. (level 2 evidence)

LOMA LINDA UNIVERSITY
MEDICAL CENTER

Trauma surgeon's perspective

- Summary
- As with any disease process, multidisciplinary perspective and understanding is important.
- By understanding the trauma's surgeons perspective, we can better assist them caring for their patients.

LOMA LINDA UNIVERSITY
MEDICAL CENTER

VIR response times

- Resources for Optimal Care of the Injured Patient (aka the "Orange book")
  - "In Level I and II trauma centers qualified radiologists must be available within **30 minutes** to perform complex imaging studies, or interventional procedures."
- Subsequently, investigators began to analyze trauma VIR response times with clinical outcomes.



LOMA LINDA UNIVERSITY
MEDICAL CENTER

VIR response times

- Tesoriero et al. (JTACS 2017)
  - Retrospective review of patients with pelvic fractures who underwent angiography at Maryland Shock Trauma from 2002 to 2012.
  - Charts were analyzed for time to angiography, embolization, and mortality.
  - 4712 patients with pelvic fractures
  - 344 (7.3%) underwent pelvic angiography.

LOMA LINDA UNIVERSITY
MEDICAL CENTER

TABLE 6. Mortality in Relation to Hemodynamics at Presentation, Receipt of Massive Transfusion, and Time to Angiography

	Mortality		
	Overall n (%)	**Hemorrhage n (%)**	**Sepsis/MODS* n (%)**
All (n = 344)	**62 (17.7)**	22 (35.5)	27 (43.5)
Embolized (n = 212)	**40 (18.8)**	13 (32.5)	17 (42.5)
HI at admission (n = 151)	**42 (27.8)**	15 (35.7)	19 (45.2)
Massive transfusion (n = 104)	**43 (41.3)**	19 (44.2)	14 (32.5)
Time to angiography, minutes			
≤90 (n = 3)	**2 (66.7)**	2 (100)	
91–120 (n = 21)	**5 (23.8)**	4 (80)	1 (20)
121–180 (n = 30)	**5 (16.7)**	3 (60)	2 (40)
181–240 (n = 58)	**19 (32.8)**	7 (36.8)	11 (57.9)
241–300 (n = 72)	**15 (20.8)**	4 (26.7)	6 (40)
>300 (n = 160)	**16 (10)**	2 (12.5)	7 (43.8)

*MODS, multiple-organ dysfunction syndrome.

LOMA LINDA UNIVERSITY
MEDICAL CENTER

TABLE 6. Mortality in Relation to Hemodynamics at Presentation, Receipt of Massive Transfusion, and Time to Angiography

	Mortality		
	Overall n (%)	Hemorrhage n (%)	Sepsis/MODS* n (%)
All (n = 344)	**62 (17.7)**	22 (35.5)	27 (43.5)
Embolized (n = 212)	**40 (18.8)**	13 (32.5)	17 (42.5)
HI at admission (n = 151)	**42 (27.8)**	15 (35.7)	19 (45.2)
Massive transfusion (n = 104)	**43 (41.3)**	19 (44.2)	14 (32.5)
Time to angiography, minutes			
≤90 (n = 3)	**2 (66.7)**	2 (100)	
91–120 (n = 21)	**5 (23.8)**	4 (80)	1 (20)
121–180 (n = 30)	**5 (16.7)**	3 (60)	2 (40)
181–240 (n = 58)	**19 (32.8)**	7 (36.8)	11 (57.9)
241–300 (n = 72)	**15 (20.8)**	4 (26.7)	6 (40)
>300 (n = 160)	**16 (10)**	2 (12.5)	7 (43.8)

*MODS, multiple-organ dysfunction syndrome.

LOMA LINDA UNIVERSITY
MEDICAL CENTER

VIR response times

- Tesoriero et al. (JTACS 2017)
  - The highest mortality rates
    - < 90 min (66%)
    - 181-240 min (32.8%).
  - Multivariate regression analysis showed that time to angiography **was not associated with mortality**.

LOMA LINDA UNIVERSITY
MEDICAL CENTER

VIR response times

- Matsushima et al. (JTACS 2018)
  - 2-year retrospective cohort study using the ACS-TQIP database from January 2013 to December 2014.
  - Patients with blunt pelvic fracture with pelvic angioembo (AE) within 4 hours of admission.
  - Logistic regression was performed to evaluate time-to-AE on mortality.
  - 181 patients were analysed.

LOMA LINDA UNIVERSITY
MEDICAL CENTER

Table 3. Hierarchical logistic regression analysis for 24-hour and in-hospital mortality

Variable	24-hour mortality* Odds ratio (95% CI)	24-hour mortality* p value	In-hospital mortality* Odds ratio (95% CI)	In-hospital mortality* p value
Patient characteristics				
Age, increase 10 years	1.27 (0.93-1.71)	0.12	1.24 (0.995-1.5[illegible])	0.056
SBP, increase 10 mmHg	-	-	0.8[illegible] (0.7[illegible]-0.9[illegible])	[illegible]4
GCS, increase 1 point	0.90 (0.81-0.996)	0.04	0.88 (0.81-[illegible]6)	0.003
ISS, increase 10 points	-	-	[illegible] (1.2-2.8[illegible])	<0.001
Hours to pelvic AE, increase 1 hour	1.39 (0.76-2.55)	[illegible]	[illegible] (1.11-2.91)	0.018
Trauma center level				
Level 1 (ref)	-	-	1	
Level 2	-	-	0.18 (0.03-1.24)	0.08
Teaching status				
University hospital (ref)	1		1	
Non-teaching hospital	[illegible] (0.2[illegible]-0.83)	0.91	1.82 (0.59-5.59)	0.30
Community hos[illegible]	[illegible]00 (0.37-10.81)	0.42	5.66 (0.49-65.79)	0.17

*Hosm[illegible]-Lemeshow Goodness-of-Fit Test: p=0.11, AUROC=0.69 (95% CI: 0.59-0.83)
[illegible] Lemeshow Goodness-of-Fit Test: p=0.20, AUROC=0.81 (95% CI: 0.74-0.87)

LOMA LINDA UNIVERSITY
MEDICAL CENTER

Table 3. Hierarchical logistic regression analysis for 24-hour and in-hospital mortality

Variable	24-hour mortality* Odds ratio (95% CI)	24-hour mortality* p value	In-hospital mortality* Odds ratio (95% CI)	In-hospital mortality* p value
Patient characteristics				
Age, increase 10 years	1.27 (0.93-1.71)	0.12	1.24 (0.995-1.5[illegible])	0.056
SBP, increase 10 mmHg	-	-	0.8[illegible] (0.7[illegible]-0.9[illegible])	[illegible]4
GCS, increase 1 point	0.90 (0.81-0.996)	0.04	0.88 (0.81-[illegible]6)	0.003
ISS, increase 10 points	-	-	[illegible] (1.2-2.8[illegible])	<0.001
Hours to pelvic AE, increase 1 hour	1.39 (0.76-2.55)	[illegible]	[illegible] (1.11-2.91)	0.018
Trauma center level				
Level 1 (ref)	-	-	1	
Level 2	-	-	0.18 (0.03-1.24)	0.08
Teaching status				
University hospital (ref)	1		1	
Non-teaching hospital	[illegible] (0.2[illegible]-0.83)	0.91	1.82 (0.59-5.59)	0.30
Community hos[illegible]	[illegible]00 (0.37-10.81)	0.42	5.66 (0.49-65.79)	0.17

*Hosm[illegible]-Lemeshow Goodness-of-Fit Test: p=0.11, AUROC=0.69 (95% CI: 0.59-0.83)
[illegible] Lemeshow Goodness-of-Fit Test: p=0.20, AUROC=0.81 (95% CI: 0.74-0.87)

ACCEPTED

LOMA LINDA UNIVERSITY
MEDICAL CENTER

VIR response times

- Matsushima et al. (JTACS 2018)
  - Longer time-to-pelvic AE was significantly associated with increased in-hospital mortality (odds ratio: 1.79 for each hour, p=0.018).
  - These results suggest that trauma centers should allocate resources to minimize delays in performing pelvic AE.

LOMA LINDA UNIVERSITY
MEDICAL CENTER

VIR response times

- Summary
  - Discrepant data outcomes when analyzing time to angiography and mortality.
  - However, these types of program metrics are becoming more important for state and ACS trauma program certification/designation

Nonselective internal iliac artery embolization

Nonselective internal iliac artery embolization

- When to use it?
- How safe is it?
- Evidence to support it?

Nonselective internal iliac artery embolization

- When to use nonselective internal iliac embolization
  - No standard practice pattern
  - If the patient is hemodynamically unstable and a negative angiogram for extravasation?
  - CT scan demonstrating acute hemorrhage with a negative angiogram for extravasation?
  - If there are multiple sites of extravasation identified?

Nonselective internal iliac artery embolization

- How safe is nonselective internal iliac embolization?

Nonselective internal iliac artery embolization

- How safe is nonselective internal iliac embolization?
- Complications
  - Gluteal muscle necrosis
  - AVN of femur
  - Nerve palsy (Sciatic nerve or crural nerve)
  - Bowel infarction
  - Bladder necrosis

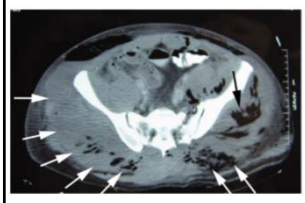

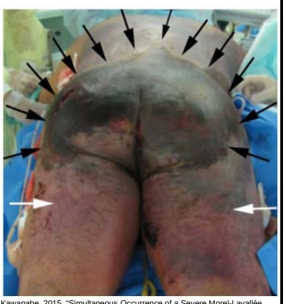

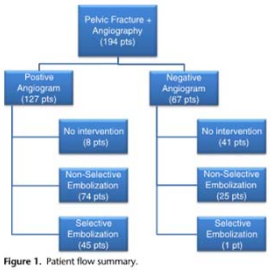

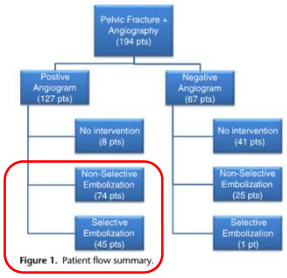

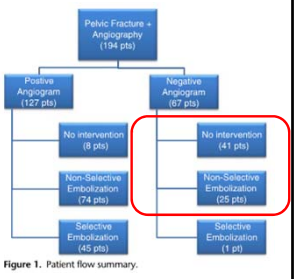

Is it safe to use?

Shimizu, Takayoshi, Shuichi Matsuda, Atsushi Sakuragi, Tomio Tsukie, and Keiichi Kawanabe. 2015. “Simultaneous Occurrence of a Severe Morel-Lavallée Lesion and Gluteal Muscle Necrosis as a Sequela of Transcatheter Angiographic Embolization Following Pelvic Fracture: A Case Report.” *Journal of Medical Case Reports* 9 (March): 69.

Is it safe to use?

Ali, Ahmed, Ghulam Nabi, Satchi Swami, and Bhaskar Somani. 2014. “Bladder Necrosis Secondary to Internal Iliac Artery Embolization Following Pelvic Fracture.” *Urology Annals* 6 (2): 166–68.

Nonselective internal iliac artery embolization

- Evidence for/against nonselective internal iliac embolization
  - Hymel et al. (JTACS 2017)
  - In cases of negative angiogram, does nonselective embolization aid in hemorrhage control?
  - In cases of positive angiogram, is nonselective or selective embolization superior?

Nonselective internal iliac artery embolization

- Hymel et al. (JTACS 2017)
- A multicenter retrospective review of patients with pelvic fractures who underwent angiography between 2002 and 2014.

Figure 1. Patient flow summary.

Nonselective internal iliac artery embolization

- Hymel et al. (JTACS 2017)
- A multicenter retrospective review of patients with pelvic fractures who underwent angiography between 2002 and 2014.

Figure 1. Patient flow summary.

Nonselective internal iliac artery embolization

- Hymel et al. (JTACS 2017)
- A multicenter retrospective review of patients with pelvic fractures who underwent angiography between 2002 and 2014.

Figure 1. Patient flow summary.

Nonselective internal iliac artery embolization

- Hymel et al. (JTACS 2017)
- Negative angiogram for bleeding: no embolization vs embolization
  - Blood requirements in the first 24 hours favored the embolization group (7.5 vs. 4.0, p = 0.054).
  - No difference in the rate of embolization-related complications (11.4% vs. 6.0%, p = 0.414).
  - No statistically significant differences in length of hospital stay (8.3 d vs 7.3 d, p = 0.486)
  - No statistically significant differences in mortality rates (9.8 vs 19.2, p = 0.280)

Nonselective internal iliac artery embolization

- Hymel et al. (JTACS 2017)
- Positive angiogram for bleeding – nonselective (NSE) vs selective (SE) embolization
  - No differences in transfusion requirements (14.5 vs. 12.0, p = 0.420).
  - No differences in mortality (27.6% vs. 18.4%, p = 0.276).
  - No difference in the rate of embolization-related complications (4.1% vs. 2.1%, p = 0.352).
  - Worse rate of thromboembolic complications in the NSE group (12.1% vs. 0, p = 0.010).

Nonselective internal iliac artery embolization

- Hymel et al. (JTACS 2017)
  - Embolization in the face of a negative angiogram may aid in hemorrhage control for those patients being actively transfused.
  - If embolized, then selective occlusion of more distal vessels, rather than of the main internal iliac artery, should be performed.

Learning objectives

- Current concepts and management of pelvic trauma
- Unusual case of penetrating trauma
- Atypical management of GI bleeding

Case

- 38 year old female no pertinent PMHx presenting with GSW to left chest with chest pain and dyspnea.
- BP 77/41
- HR 142

Case

- Patient rushed to OR
- Intraoperatively findings
  - Pericardial tamponade
  - Penetrating injury to the right ventricle
  - No bullet found

Case

- Patient rushed to OR
- Intraoperative findings
  - Pericardial tamponade
  - Penetrating injury to the right ventricle
  - No bullet found
- C-arm fluoroscopy

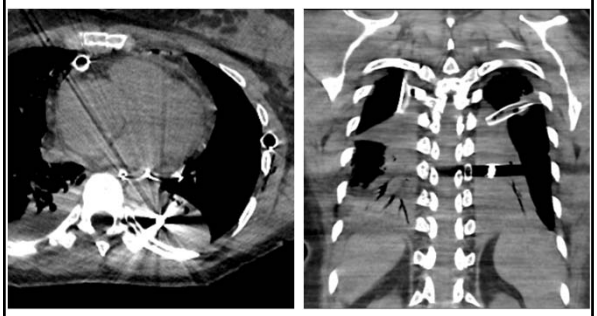

Case

- VIR consulted for management.
- Right femoral vein access
- 18F sheath in the IVC
- Flush catheter advanced in to the left PA
- Angiogram demonstrates bullet in a left lower lobe segmental branch

Case

- Left lower lobe segmental PA branch was catheterized with Kumpe and 0.035-in Glideadvantage.
- Exchanged for an Amplatz Gooseneck snare and bullet pulled to the sheath
- However, the bullet would not fit into the sheath.

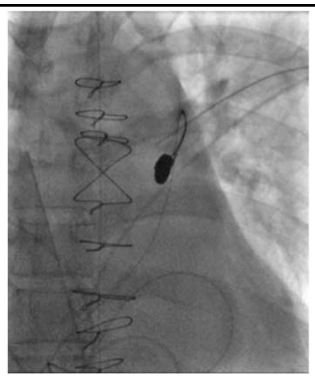

Case

- Vascular surgery performed a femoral cutdown and retreived the sheath and bullet.

Venous bullet embolization

- Bullet emboli are initially characterized as arterial, venous, or paradoxical.
- Venous bullet emboli can gain entry to the venous circulation from nearly any point of injury.
- Complications of venous bullet emboli
  - Cardiac valvular destruction
  - Venous thrombosis
  - Dysrhythmias
  - Severe hypoxia secondary to pulmonary arterial emboli.

Venous bullet embolization

- A review of the literature from 1987 to 2010 revealed 45 cases from 42 publications.
- Management patterns were often dictated by the timing of discovery, anatomical location, and the presence or absence of symptoms.
  - 58% of injuries underwent intervention,
    - Open surgical removal (18/45)
    - Endovascular removal (6/45)
    - Hybrid open/endovascular (2/45).

Venous bullet embolization

- More than 30% (14/45) of cases were managed by careful observation
  - Majority with the bullet within the pulmonary artery and asymptomatic.
- Debate continues as to how best manage these patients.

Venous bullet embolism management

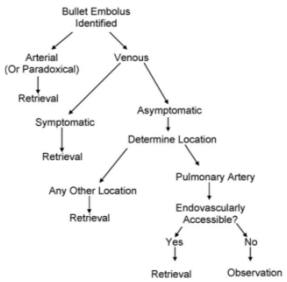

Miller, Keith R., Matthew V. Benns, Jason D. Sciarretta, Brian G. Harbrecht, Charles B. Ross, Glen A. Franklin, and Jason W. Smith. 2011. "The Evolving Management of Venous Bullet Emboli: A Case Series and Literature Review." *Injury* 42 (5): 441–46.

Venous bullet embolization

- Summary
- Management of bullet embolism depends on:
  - Arterial vs venous vs paradoxical
  - Location
  - Symptomatology

Learning objectives

- Current concepts and management of pelvic trauma
- Unusual case of penetrating trauma
- Atypical management of GI bleeding

Case

- 59 year old female with esophageal carcinoma, s/p chemoradiation and esophageal stent placement
- Presents to OSH after ground level fall resulting in massive hematemesis.
- Transfused 3 pRBC. Transferred directly to MICU at LLUMC.

Case

- VIR consulted for management for upper GI bleeding.
- Aortogram demonstrates active extravasation from the aorta into the esophageal stent.
- Emergent page made to vascular surgery for consultation.
- While we wait. . .
  - Coda balloon?
  - Any other options?

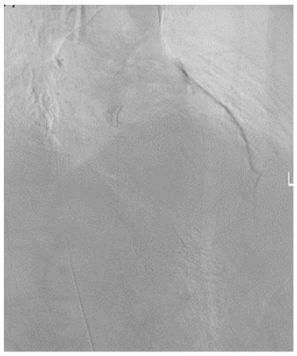

LOMA LINDA UNIVERSITY
MEDICAL CENTER

Case

- Using a Sos catheter and an 0.035-in Glidewire advantage, the aortoesophageal fistula was cannulated.

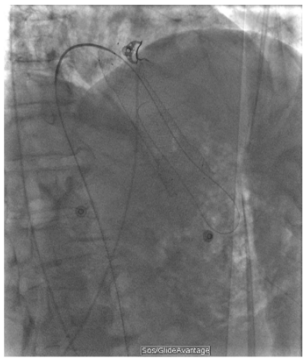

LOMA LINDA UNIVERSITY
MEDICAL CENTER

Case

- The catheter was exchanged for a fogarty occlusion balloon and pulled back to occlude the fistula.

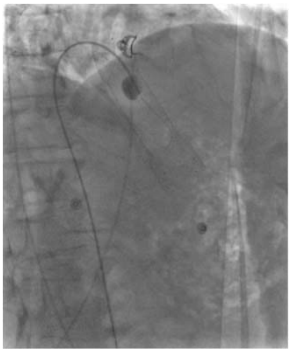

LOMA LINDA UNIVERSITY
MEDICAL CENTER

Case

- Temporary occlusion until vascular surgery arrival.

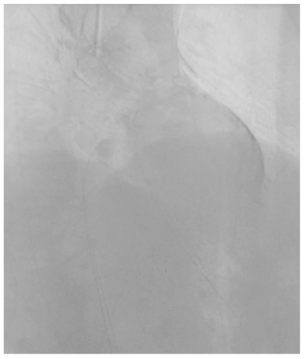

LOMA LINDA UNIVERSITY
MEDICAL CENTER

Case

- In conjunction with vascular surgery, a 26 mm x 10 cm Gore TAG stent was deployed

LOMA LINDA UNIVERSITY
MEDICAL CENTER

Case

- Post dilatation with a 32 mm Coda balloon.
- No further extravasation seen.
- However, patient eventually expired due to complicated hospital course and DNR directive.

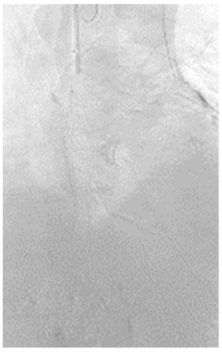

LOMA LINDA UNIVERSITY
MEDICAL CENTER

Aortoesophageal fistula

- Aortoesophageal fistula is a life-threatening cause of gastrointestinal bleeding
- Etiology
  - Thoracic aortic aneurysm
  - Foreign body ingestion
  - Esophageal malignancy
  - Postoperative complications.

LOMA LINDA UNIVERSITY
MEDICAL CENTER

Aortoesophageal fistula

- Chiari's triad
  - Midthoracic pain
  - Sentinel arterial hemorrhage
  - Exsanguination after a symptom-free interval
- The identification of massive upper gastrointestinal hemorrhage that is bright red and arterial in nature is characteristic.
- Aortography may be useful during active hemorrhage to demonstrate the fistula, but results of aortography may be negative during the symptom-free interval.

LOMA LINDA UNIVERSITY
MEDICAL CENTER

Aortoesophageal fistula

- Morrison et al. (JVIR 2016)
  - Dotter Interventional Institute placed 22 mm Hercules esophageal dilation balloon transorally for tamponade after massive hemorrhage during attempted esophageal stent removal. Esophageal stent placed for CA, with removal for hemoptysis.
  - IR placed TAG stent.
  - Discovered Esophageal balloon had transgressed the AEF and was in aortic lumen. Stent was then fully expanded.

LOMA LINDA UNIVERSITY
MEDICAL CENTER

Summary

- Current concepts and management of pelvic trauma
- Unusual case of penetrating trauma
- Atypical management of GI bleeding

LOMA LINDA UNIVERSITY
MEDICAL CENTER

References

- The Eastern Association for the Surgery of Trauma. n.d. "Pelvic Fracture Hemorrhage-Update and Systematic Review - Practice Management Guideline." Accessed January 31, 2018. https://www.east.org/education/practice-management-guidelines/pelvic-fracture-hemorrhageupdate-and-systematic-review.
- Tesoriero, Ronald Brian, Brandon R. Bruns, Mayur Narayan, Joseph Dubose, Sundeep S. Guliani, Megan L. Brenner, Sharon Boswell, Deborah M. Stein, and Thomas M. Scalea. 2017. "Angiographic Embolization for Hemorrhage Following Pelvic Fracture: Is It 'time' for a Paradigm Shift?" *The Journal of Trauma and Acute Care Surgery* 82 (1): 18.
- Matsushima, Kazuhide, Alice Piccinini, Morgan Schellenberg, Vincent Cheng, Patrick Heindel, Aaron Strumwasser, Elizabeth Benjamin, Kenji Inaba, and Demetrios Demetriades. 2018. "Effect of Door-to-Angioembolization Time on Mortality in Pelvic Fracture: Every Hour of Delay Counts." *The Journal of Trauma and Acute Care Surgery* Publish Ahead of Print (January). Journal of Trauma and Acute Care Surgery. https://doi.org/10.1097/TA.0000000000001803.
- "Endovascular Today - Transcatheter Embolization for Trauma of the Pelvis." n.d. Endovascular Today. Accessed March 31, 2018. https://evtoday.com/2014/09/transcatheter-embolization-for-trauma-of-the-pelvis/.
- Urquia, Arlen, Jesus Aldea Martinez, Laura Adrián Lozano, José Luis López Martínez, and Miguel Angel Castaño Blazquez. 2012. "Arterial Embolization in Postpartum Hemorrhage," January. European Congress of Radiology 2012. http://posterng.netkey.at/esr/viewing/index.php?module=viewing_poster&pi=108997.
- "MRA Planning Halves Radiation, Contrast Dose during UAE." n.d. AuntMinnie.com. Accessed March 31, 2018. https://www.auntminnie.com/index.aspx?sec=ser&sub=def&pag=dis&ItemID=85941.
- Scemama, U., A. Dabadie, A. Varoquaux, J. Soussan, C. Gaudon, G. Louis, K. Chaumoître, and V. Vidal. 2015. "Pelvic Trauma and Vascular Emergencies." *Diagnostic and Interventional Imaging* 96 (7-8): 717–29.
- Shimizu, Takayoshi, Shuichi Matsuda, Atsushi Sakuragi, Tomio Tsukie, and Keiichi Kawanabe. 2015. "Simultaneous Occurrence of a Severe Morel-Lavallée Lesion and Gluteal Muscle Necrosis as a Sequela of Transcatheter Angiographic Embolization Following Pelvic Fracture: A Case Report." *Journal of Medical Case Reports* 9 (March): 69.
- Ali, Ahmed, Ghulam Nabi, Satchi Swami, and Bhaskar Somani. 2014. "Bladder Necrosis Secondary to Internal Iliac Artery Embolization Following Pelvic Fracture." *Urology Annals* 6 (2): 166–68.

LOMA LINDA UNIVERSITY
MEDICAL CENTER

References

- Hymel, Aimee, Sabrina Asturias, Frank Zhao, Ryan Bliss, Thea Moran, Richard H. Marshall, Elizabeth Benjamin, et al. 2017. "Selective versus Nonselective Embolization versus No Embolization in Pelvic Trauma: A Multicenter Retrospective Cohort Study." *The Journal of Trauma and Acute Care Surgery* 83 (3): 361–67.
- Miller, Keith R., Matthew V. Benns, Jason D. Sciarretta, Brian G. Harbrecht, Charles B. Ross, Glen A. Franklin, and Jason W. Smith. 2011. "The Evolving Management of Venous Bullet Emboli: A Case Series and Literature Review." *Injury* 42 (5): 441–46.
- Morrison et al. Exsanguinating Aortesophageal Fistula: A Herculean Effort. JVIR. Vol 27. Issue 8. Pages 1226-1227. August 2016.

LOMA LINDA UNIVERSITY
MEDICAL CENTER

Acknowledgements

- Jeffrey Hsu, M.D. - Program Chair Kaiser 2018
- David Rajaratnam, M.D. – Kaiser San Bernardino
- Ray Hung, M.D. – Kaiser San Bernardino
- Sharon Kiang, M.D. – LLUMC
- Jalil Kalantari, M.D. - LLUMC
- Jason Smith, M.D. – LLUMC
- David Moon, M.D. – LLUMC

LOMA LINDA UNIVERSITY
MEDICAL CENTER

Thank you

Roger Tomihama, M.D.
rtomihama@llu.edu

LOMA LINDA UNIVERSITY
MEDICAL CENTER