Endoscopic Management of Vascular Lesions of the GI tract

ALBERTA DIGESTIVE DISEASE SUMMIT

Lake Louise, June 2014

Sergio Zepeda-Gómez MD
Assistant Professor
Division of Gastroenterology
University of Alberta, Edmonton

Table 3. Causes of upper gastrointestinal bleeding (adapted from Ref. [37]).

Diagnosis	Frequency (%)
Duodenal ulcer	24.3
Gastric erosions	23.4
Gastric ulcer	21.3
Varices	10.3
Mallory–Weiss tear	7.2
Oesophagitis	6.3
Erosive duodenitis	5.8
Neoplasm	2.9
Miscellaneous	10.3

Best Practice & Research GI, 2008

Nomenclature

Angiodysplasia
Arterio-venous malformations
Teleangectasia
Phlebectasia
Hemangioma
Angiosarcomas
Gastric Antral Vascular Ectasia
Dieulafoy's lesion

Vascular Lesions: Classification

Neoplastic Lesions

1) **Endothelial cell tumors**
(hemangiomas, phlebectasias, hemangioendotheliomas, angiosarcomas)

2) **Other vascular tumors**
(Hemangioperycitomas, Kaposi Sarcoma)

Non-Neoplastic malformations

1) **Inflammatory: vasculitis**
2) **Obstructive: Ischemic**
3) **Structural Malformations**
(angiodysplasias)

Best Pract Res Clin Gastroenterol 2001

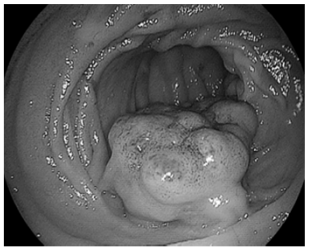

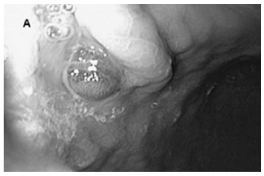

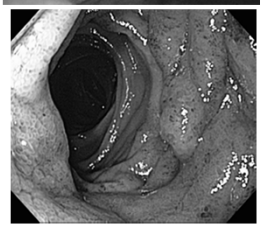

Vascular Lesions: Classification

Neoplastic Lesions

1) **Endothelial cell tumors**
(hemangiomas, phlebectasias, hemangioendotheliomas, angiosarcomas)

2) **Other vascular tumors**
(Hemangioperycitomas, Kaposi Sarcoma)

Non-Neoplastic malformations

1) **Inflammatory: vasculitis**
2) **Obstructive: Ischemic**
3) **Structural Malformations**
(angiodysplasias)

Categories of vascular malformations according to anatomy and pathophysiology

Most affected vascular structure	Lesions, Syndromes, Diseases
Venous	Varices
	Hemorrhoids
Capillary	Gastric Antral Vascular Ectasia (GAVE)
	Portal gastropathy
Arterio-venous	Angiodysplasia/Teleangectasia
Arterial	Dieulafoy's

Best Practice & Research GI, 2008

Angiodysplasia

Arterio-venous type of vascular lesion

- Small veins, capillaries and arteries: dilated, tortuous, thin-walled veins, thick-walled arteries. No inflammation or fibrosis.
- Common source of bleeding from SB in pts older than 50-60 yrs
- Up to 5-6% of cases of GI bleeding caused by angiodysplasia in upper or lower GI tract.

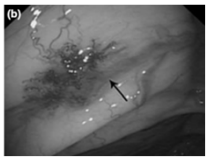

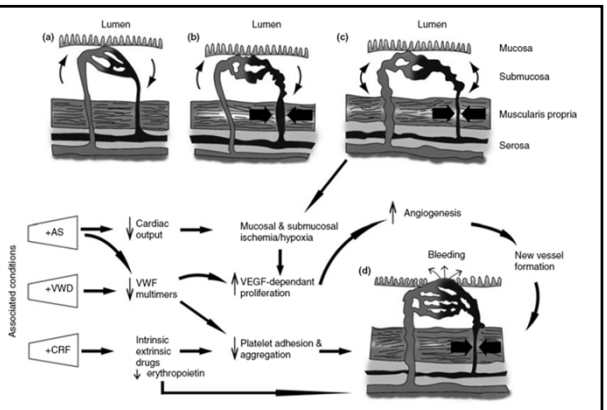

Aliment Pharmacol Ther, 2014

Dieulafoy's Lesion

Arterial type of vascular abnormality

- Submucosal end arteries are abnormally large (calibre-persistent artery) that protrude to mucosa
- More frequent location: cardias, fundus
- Bleeding: from tiny erosion on the surface, no inflammation at the edge of the mucosal defect.
- It may cause massive bleeding

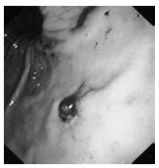

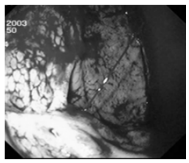

Gastric Antral Vascular Ectasia (GAVE)

Capillary-type vascular lesion

- Pathology: dilated, tortuous mucosal capillaries often occluded by thrombus.
- Endoscopy: multiple red stripes that radiate to the pylorus or diffuse lesions with small, flat spots (autoimmune or connective tissue disorders, portal hypertension).

GAVE

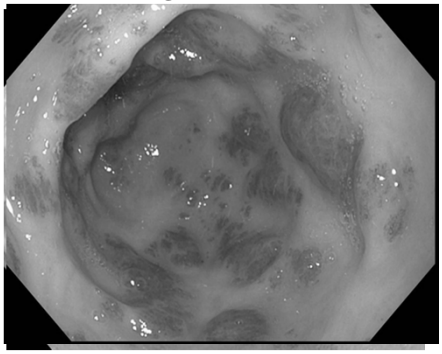

Endoscopic Classification of vascular lesions in small bowel

Type 1a:	Punctulate erythema (less than 1 mm) with or without oozing
Type 1b:	Patchy erythema (a few mm) with or without oozing
Type 2a:	Punctulate lesions (less than 1 mm) with pulsatile bleeding
Type 2b:	Pulsatile red protrusion without surrounding venous dilatation
Type 3:	Pulsatile red protrusion with surrounding venous dilatation
Type 4:	? Other lesions not classified into any of the above categories

Yano T, et al. *Gastrointest Endosc* 2008

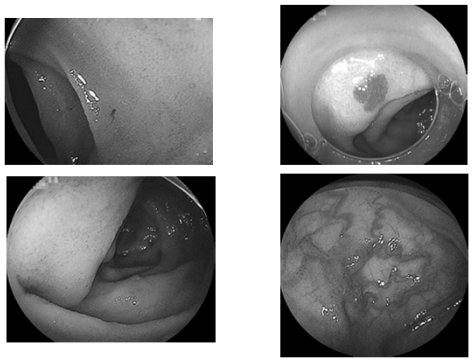

Treatment of Vascular Lesions

Endoscopic:
APC
Electrocoagulation
Hemoclips
Band ligation
Injection therapy

Pharmacologic:
Hormonal therapy
Octreotide
Thalidomide

Surgery
Interventional Radiology

Angiodysplasia

Dieulafoy

GAVE
Criotherapy
RFA

Medical and Endoscopic Therapies for Angiodysplasia and Gastric Antral Vascular Ectasia: A Systematic Review

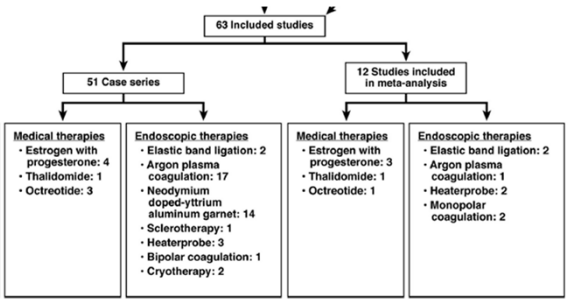

Figure 1. Search strategy and results.

Clinical Gastroenterology and Hepatology 2014

Medical and Endoscopic Therapies for Angiodysplasia and Gastric Antral Vascular Ectasia: A Systematic Review

Table 3. Evidence for Therapies

Type of therapy	Angiodysplasia	GAVE
Estrogen with progesterone	–	I
Octreotide	+	X
Thalidomide	+	X
EBL	I	I
APC	I	–
Nd:YAG laser	I	–
Heater probe	I	I
Monopolar coagulation	I	I
Bipolar coagulation	I	X
Sclerotherapy	I	X
Cryotherapy	X	I

+, Evidence for use; –, evidence against use; I, insufficient data; X, no data.

Clinical Gastroenterology and Hepatology 2014

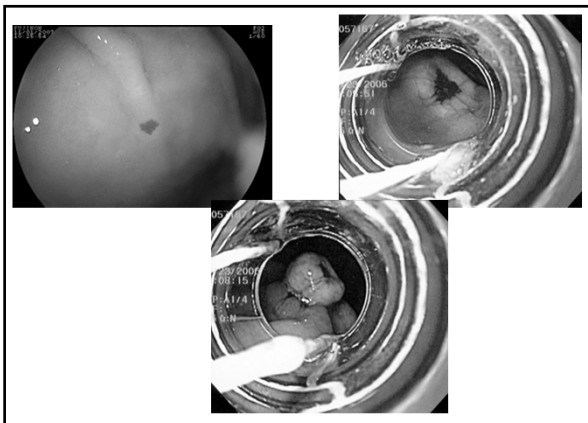

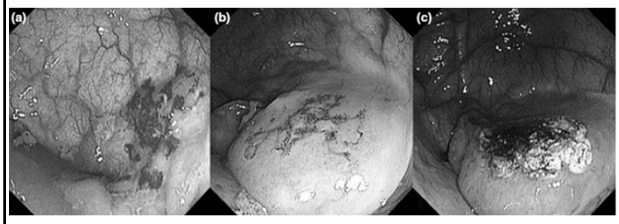
(a)
(b)
(c)

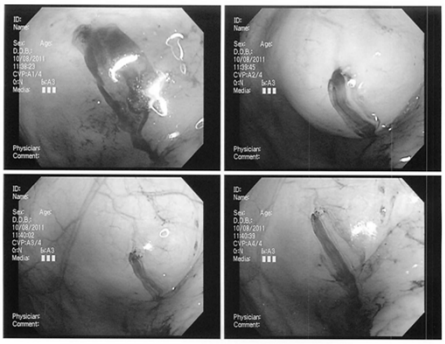

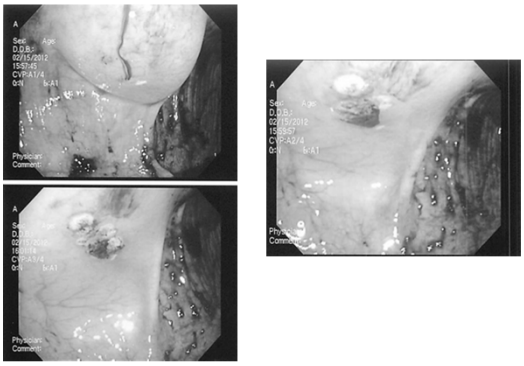


FUJINON
2013/06/17
14:56:46
M60 F00
AVE
1/60
A1 NHS

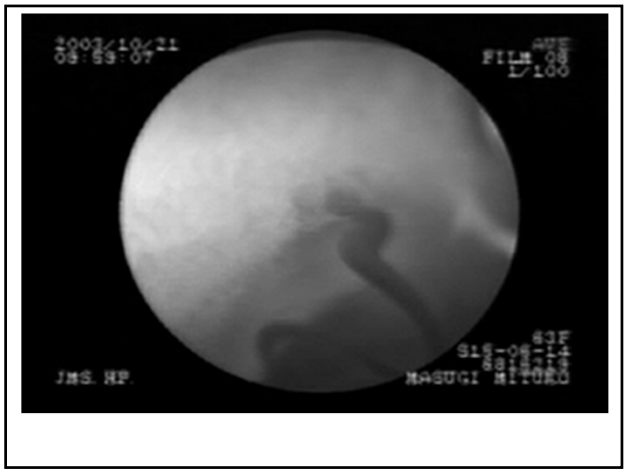
2003/10/21
09:59:07
AVE
FILM 08
1/100
63F
S15-06-14
JMS. HP.
MASUGI MITORO

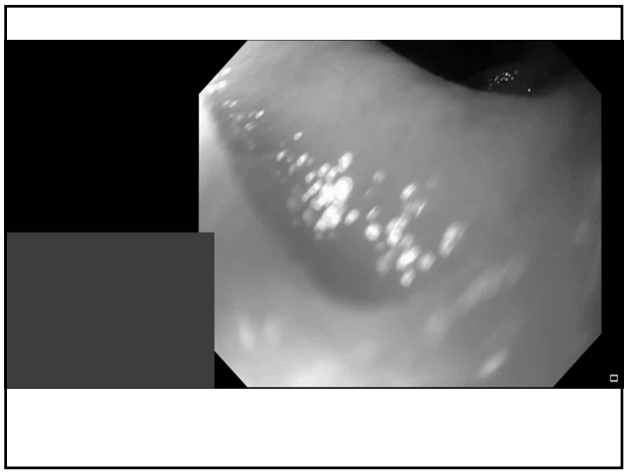

GAVE: endoscopic treatment

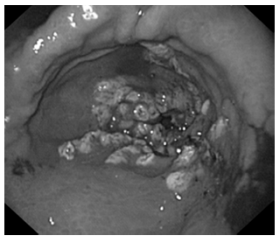

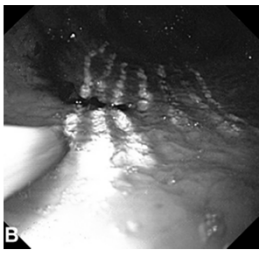

Treatment of gastric antral vascular ectasia (watermelon stomach) with endoscopic band ligation

Christopher D. Wells, MD, M. Edwyn Harrison, MD, Suryakanth R. Gurudu, MD, Michael D. Crowell, PhD, Thomas J. Byrne, MD, Giovanni DePetris, MD, Virender K. Sharma, MD

Scottsdale, Arizona, USA

TABLE 3. ANCOVA evaluating group differences between EBL and ETT after controlling for number of preprocedure transfusions and admissions, length of follow-up, and number of treatment sessions

Outcome neasures	ETT (n = 13) (mean [SD])	EBL (n = 9) (mean [SD])	*F* (1,15)*	*P* value
Posttreatment bleeding (%)	82 (41)	33 (50)	4.81	.046
Posttreatment transfusions	6.45 (14.87)	0.89 (2.03)	9.62	.008
Posttreatment hospitalizations	1.18 (1.78)	0.11 (0.33)	7.65	.015

*Degrees of freedom for the *F*-test statistic.

(Gastrointest Endosc 2008;68:231-6.)

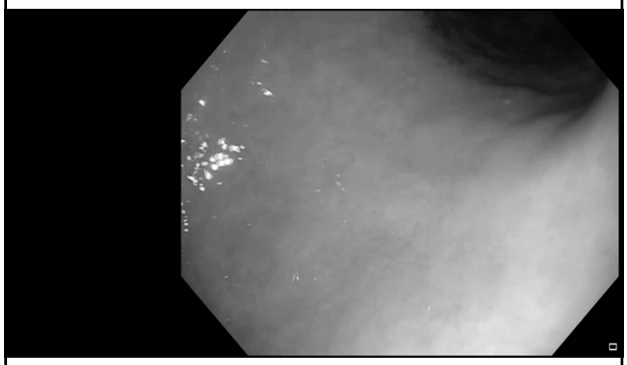

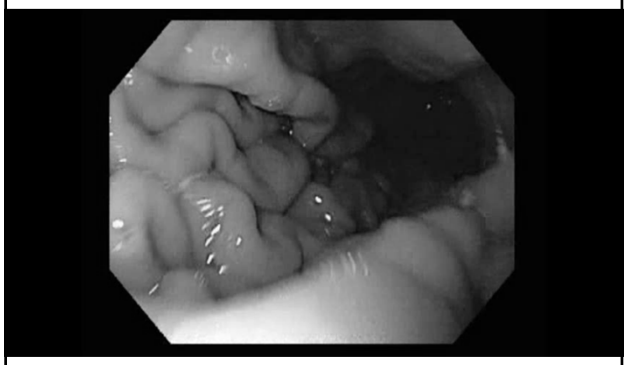

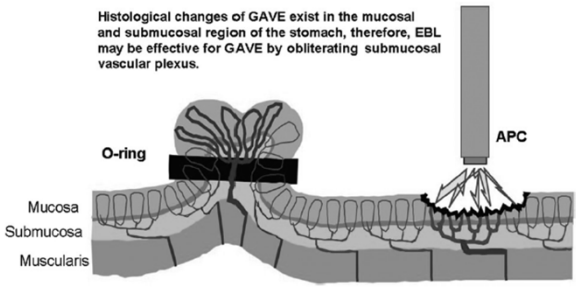

Digestive Endoscopy, 2012

Summary

- Vascular malformations are been recognized more frequently as a cause of bleeding in the GI tract.
- Endoscopic therapy include APC, thermal, injection, hemoclips and more recently band ligation.
- Well designed randomized controlled trials are needed to determine the efficacy and complications of endoscopic treatment for vascular lesions in the GI tract.

References

1) Gordon FH, et al. Vascular malformations of the Gastrointestinal Tract. *Best Pract Res Clin Gastroenterol* 2001
2) Sami S, et al. Gastrointestinal Angiodysplasia – pathogenesis, diagnosis and management. *Alim Pharmacol Ther*, 2014
3) Regula J, et al. Vascular lesions of the gastrointestinal tract. . *Best Pract Res Clin Gastroenterol* 2008
4) Fuccio L, et al. Diagnosis and management of gastric antral vascular ectasia. *World J Gastrointest Endosc*, 2013
5) Swanson E, et al. Medical and endoscopic therapies for angiodysplasia and gastric antral vascular ectasia: a systematic review. *Clin Gastroenterol Hepatol*, 2014
6) Baxter M, et al. Dieulafoy's lesion. Current trends in diagnosis and management. *Ann R Coll Surg Engl*, 2010
7) Yano T, et al. Endoscopic Classification of vascular lesions in small bowel. *Gastrointest Endosc* 2008
8) Sato T, et al. EBL vs APC for gastric antral vascular ectasia associated with liver diseases. *Dig Endoscopy* 2012