UNIVERSITY of HOUSTON
COLLEGE of OPTOMETRY

The Use of Image Guided Scleral and Corneal Mapping on a Re-emerging Keratoconus following Penetrating Keratoplasty

Christina S. Abuata, OD, Jan P.G. Bergmanson, OD, PhD, PhD hc, DSc, FCOptopm, FAAO, FSLS

TEXAS EYE RESEARCH TERTC & TECHNOLOGY CENTER

BACKGROUND

- Corneal transplantation is one of the most successful organ transplants performed in humans, averaging up to 40,000 surgeries annually.[1]
- Medical scleral lenses (SL) are remarkable options to rehabilitate vision in patients after a corneal transplant.
- Up to 60% of penetrating keratoplasty (PKP) patients require a contact lens post-surgery due to irregular astigmatism that spectacles cannot correct.[2]
- This case discusses a Keratoconus (Kc) patient with a history of a PK 9 years prior, that was managed with an empirical digital image guided SL design at our clinic.

CLINICAL FINDINGS

History and Chief Complaint:

A 64 year old Caucasian Male presented to the University Eye Institute for a contact lens evaluation wearing a 2 year -old Europa SL (OD) and a Biofinity (comfilicon A) soft spherical lens (OS). He reported good vision and comfort.

POHx: OD: Severe Kc s/p PK 9 years prior, **OS:** Mild Kc
PMHx: Hypertension, Hypercholesterolemia and anxiety
FOHx: Keratoconus (cousin)
Medications: Atorvastatin, Carvedilol, Ramipril, Modafinil, Trazadone HCL, Clonazepam, Cymbalta
VAcc: **OD**: 20/50-2, **OS**: 20/25-1, **OU**: 20/25-1

Biomicroscopy:

OD: Ectatic full thickness graft. Donor tissue showed area of extreme steepening and thinning. Mild haze peripherally with 2mm of neovascularization nasally in host tissue. 2+ NS cataract.
OS: Unremarkable, (-) stromal thinning, (-) vertical striae, (-) Fleischer ring
Endothelial cell count (Nidek): OD: 977 cells/mm^2, **OS:** 2138 cells/mm^2

Habitual Lenses:

OD: Europa/ 45.0D/-9.00/20.0 mm, Clearance 200µm central, harsh corneal touch over nasal part of graft
OS: Biofinity/8.6D/+2.00D/14.0 VA 20/25-1, good centration, movement and coverage

Lens Ordered:

OD: Latitude/47.14 D/-6.33 D/17.0 mm/sag 6,306 mm/ct 0.40 mm/optimum extreme VA 20/50, Clearance 116µm central, 82 µm over steepest/thinnest part of graft. Dispensed lenses.
OS: Biofinity/8.60 D/+2.00 D/14.0 VA 20/25-1, dispensed and finalized

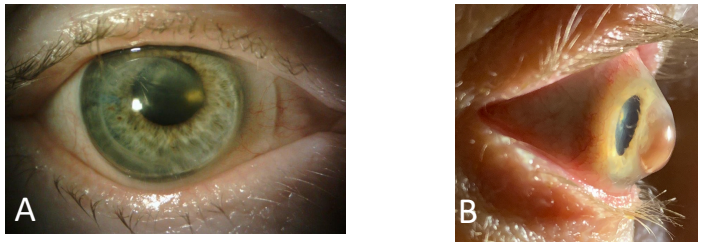

Figure 1. Biomicroscopic images of OD eye. A. Frontal view. B. Temporal view

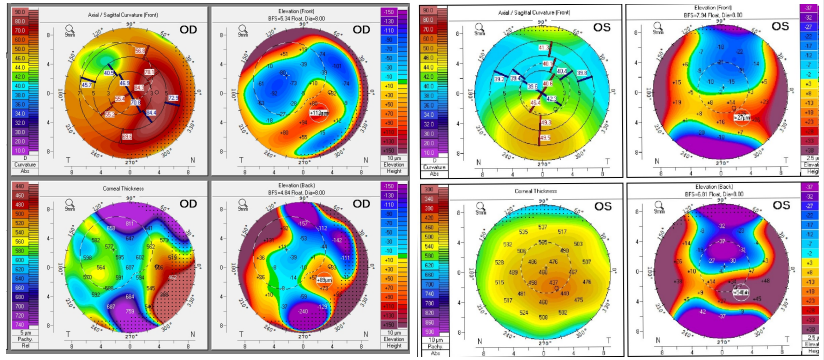

Figure 2. Pentacam Refractive Setting.
OD: Kmax: 86.7D/Thinnest point: 388 µm, OS: Kmax: 49.8D/Thinnest point: 434 µm

Figure 3. A. Digital image showing uniform fluid reservoir thickness across the OD ocular surface with the ordered image guided SL. B. Comparative digital image with a standard spherical SL on the same cornea illustrating highly variable lens clearance across the ocular surface.



Figure 4. Side by side comparison between the ordered image guided and the comparative standard spherical lenses

DISCUSSION

- Re-emergence of Kc provides a challenge in the management of post-PK in Kc patients. In this case, the marked thinning and corneal steepening of the donor tissue had occurred after approximately a decade, which is in agreement with an earlier report.[3]
- The ensuing corneal distortion required a more complex lens design, here provided by the image guided (Latitude) SL. This design uses a computerized mapping system (sMap) to construct 3-D images of the contours of the cornea and adjacent sclera utilizing fluorescein.[4]
- **In the present case the customized design allowed the extreme vaulting over a severely ectatic cornea while also avoiding bearing of a protruding and irregular surgical interface between host and donor tissues – a feat often not possible with a standard spherical SL.**
- An added advantage of the Latitude lens is that actual lens fitting is literally eliminated reducing chair time and patient inconvenience.

REFERENCES

1. Seitz B, Langenbucher A, Hager T, Janunts E, El-Husseiny M, Szentmáry N. Penetrating Keratoplasty for Keratoconus - Excimer Versus Femtosecond Laser Trephination. *Open Ophthalmol J.* 2017;11:225–240. Published 2017 Jul 31. doi:10.2174/1874364101711010225
2. Jack S. Parker, Korine van Dijk, Gerrit R.J. Melles, Treatment options for advanced keratoconus: A Goosey, J., Patel, C., & Mathew, J. (201review, Survey of Ophthalmology,Volume 60, Issue 5,2015, Pages 459-480, ISSN 0039-6257
3. Bergmanson, J., Goosey J., Patel C, Matthew J, Recurrence or Re-emergence of Keratoconus – What is the Evidence Telling Us? Literature Review and Two Case Reports. *The Ocular Surface*, *12*(4), 267–272.
4. Gregory DeNaeyer, Donald R. Sanders, Timothy S. Farajian, Surface coverage with single vs. multiple gaze surface topography to fit scleral lenses, *Contact Lens and Anterior Eye*, Volume 40,

AWKNOWLEDGEMENTS

We wish to gratefully recognize that the images in Figure 3 were provided by Ms. Megan Schwarzinger at Visionary Optics.