Marshall B. KETCHUM UNIVERSITY
Southern California College of Optometry

Contact Lens Fit Considerations for a Patient with Urrets-Zavalia Syndrome and History of Multiple Corneal Graft Failures

Jessica Sun OD, Timothy Edrington MS, OD, FAAO

BACKGROUND

Corneal transplantation via penetrating keratoplasty (PKP) can result in highly irregular corneal morphology that may complicate the success of visual rehabilitation with contact lenses. Although scleral contact lenses (ScL) can significantly aid in the medical management of these patients, they may not always serve as the best option for vulnerable corneas prone to endothelial stress. This case illustrates considerations to optimize corneal health and visual potential for a patient with a history of multiple failed corneal grafts and a fixed and dilated pupil secondary to Urrets-Zavalia syndrome.

CASE HISTORY

Demographics	67 year-old Hispanic male.
Chief Complaint	Referred by OMD for scleral lens (ScL) fit OU s/p PKP OU.
Ocular History	Keratoconus OU, s/p PKPx3 OU. Recent episode of rejection OD after most recent PKP. s/p CE PCIOL OU. s/p YAG OS. Borderline steroid induced glaucoma OU.
Ocular Medications	Latanoprost QHS OU, Brimonidine 0.2% BID OU, Cosopt BID OU, FML 0.1% QID OD and BID OS, Refresh Celluvisc QHS OU.
Medical History	Hypercholesterolemia, heart disease, hypertension.

CLINICAL FINDINGS

Distance Visual Acuity (DVA)	OD	OS
DVA (unaided)	CF @ 3 ft	$20/40^{-1}$
DVA (cc habitual spectacle Rx)	20/100	$20/30^{+2}$
DVA (cc ScL):	20/100	$20/20^{-2}$
DVA (cc ScL s/p YAG OD)	$20/50^{+2}$ PH $20/30^{+1}$	
DVA (cc ScL w/ reverse contrast chart, dim room illumination)*	20/20	

*Unable to improve BCVA to reach potential acuity OD with ScL under moderate room illumination, likely due to light scatter/diffraction from surgically dilated pupil.

Slit Lamp Evaluation	OD	OS
Cornea	Proud graft (anterior displacement from host tissue) with epithelial mottling/irregularity encroaching visual axis. Corneal neovascularization (CNV) crossing superior graft-host junction. Guttata. (-) corneal edema.	Clear and compact graft. CNV encroaching graft-host junction. (-) corneal edema.
Iris	Superior temporal sectoral iris atrophy with surgically dilated pupil.	Superior peripheral iridectomy.

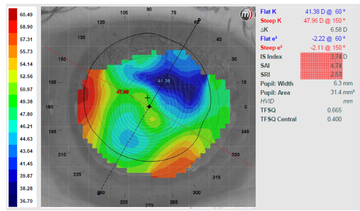

Fig 1. Corneal topography OD

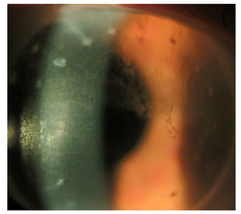

Fig 2. Epithelial mottling OD

Specular Microscopy: unable to assess endothelial cell count OU due to poor image quality.

TREATMENT & MANAGEMENT

The patient was initially fit with scleral lenses to improve visual acuity and provide adequate visualization of the posterior lens capsule OD for a YAG procedure. However, potential pinhole acuity OD could not be achieved under moderate room illumination, even s/p YAG. Because BCVA OD improved to 20/20 under dim illumination with a reverse contrast chart, an additional assessment of visual acuity was conducted with iris-occlusion soft contact lens placed over the patient's scleral lens to evaluate the effect of light scatter secondary to surgical pupil dilation on reduced BCVA OD. The patient's vision improved to $20/30^{-1}$OD after over-refraction of his scleral lens in conjunction with an iris-occlusion soft lens.

Scleral lens parameters OD: 17.0 mm DIA / oblate design / 6300 sag / 7.90 BC / CT 0.35 / Boston XO2 (dk=100)

Iris-occlusion lens parameters OD: 14.5 mm DIA / 8.60 BC / 11.5 mm iris diameter / 4.5 mm pupil / black back (dk=7.9)

Although BCVA OD improved with the addition of an iris-occlusion soft lens over a scleral lens, successful implementation was expected to be unlikely due to the concern of low oxygen permeability and chronic hypoxia. The option of piggybacking a corneal rigid gas permeable (RGP) lens on top of an iris-occlusion lens was also considered, but ultimately ruled out due to poor conformity of the soft lens to the corneal surface with excess edge fluting.

Upon re-evaluation of the feasible options for visual rehabilitation, a conservative approach was attempted to minimize the risk of corneal hypoxia as much as possible, with consideration of the patient's ultimate goal of avoiding the need for another PKP procedure. The patient was refit into an intralimbal corneal RGP lens OD with overlay spectacles for refractive correction OS to maximize oxygen exposure to both corneal grafts.

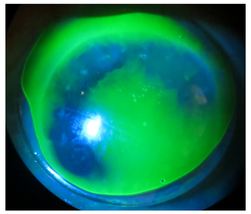

Fig 3. Intralimbal corneal RGP lens fit OD.
Parameters: 10.8 mm DIA / prolate design / 6.55 BC / 9.0 OZ / std PC / CT 0.25 / Optimum Extra (dk=100)
DVA: $20/30^{-2}$.
Fit assessment: central clearance / inferior midperipheral pooling with superior midperipheral touch / inferior edge lift

Follow-up: although acceptable initial fit and comfort were noted with an intralimbal lens, the patient ultimately decided to discontinue contact lens fitting altogether in favor of spectacle correction, as an updated manifest refraction s/p YAG OD yielded acceptable binocular vision to satisfy his lifestyle needs. The following spectacle Rx was finalized:
OD: -1.75 DS DVA: 20/80 **OS:** pl-3.00x127 DVA: 20/20

DISCUSSION

Management of this patient required contention with several factors: corneal irregularity, probable reduced endothelial functionality (s/p PKPx3), and excessive light scatter secondary to pupil dilation.

Corneal irregularity

Options to contend with irregularity and provide visual restoration:
***Corneal RGP contact lenses.** Benefits: fluid tear exchange and reduced risk of corneal ischemia. Risks: difficulty fitting over variable curvatures across the cornea, with the possibility of lens decentration or ejection. Epithelial disruption from mechanical interaction with corneal surface.

***Scleral RGP contact lenses.** Benefits: ability to vault over complex graft morphology. Risks: comparatively reduced oxygen exposure due to resistance in series from lens thickness and tear film thickness. Epithelial edema secondary to mechanical pressure/compression.

Reduced endothelial functionality

Decline in endothelial cell density (ECD) is accelerated in transplanted corneas compared to normal corneas. Reduction in ECD after transplantation with advancing age of the corneal graft can lead to graft failure due to the inability to maintain corneal deturgescence (when ECD drops to 333-500 cells/ mm^2).

Excessive light scatter secondary to pupil dilation

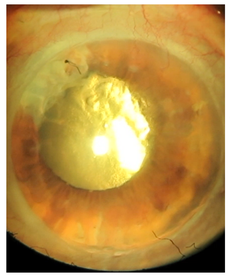

Fig 4. Fixed, dilated pupil OD with sectoral iris atrophy

Urret's Zavalia syndrome: post-operative complication of intraocular surgery, resulting in a fixed and dilated pupil unreactive to light stimulus or accommodation. Most commonly reported in cases involving PKP. Pathogenesis: associations with iris ischemia, acute elevation in intraocular pressure, and use of atropine during surgery. Treatment: option for reconstructive surgery. Anecdotal evidence reports effectiveness of sympatholytic medications and pilocarpine to induce miosis.

CONCLUSIONS

- A thorough risk versus benefit assessment is necessary in determining the most appropriate lens modality for patients with compromised corneas secondary to surgical intervention, with careful consideration of visual goals and lifestyle needs.
- Measures should be taken to reduce hypoxic and/or mechanical stress on the corneal graft, which can potentiate corneal neovascularization and endothelial decompensation. Limiting wear time and taking frequent breaks from lens wear may be appropriate.
- Frequent monitoring (e.g. 3-4 months) is indicated to ensure optimal corneal health is maintained, regardless of selected lens modality.

REFERENCES

1. Claerhout, I, et al. (2008). "Graft failure: I. Endothelial cell loss." Int Ophthalmol 28(3): 165-173.
2. Guillon, N. C, et al. (2018). "Corneal oedema in a unilateral corneal graft patient induced by high Dk mini-scleral contact lens." Cont Lens Anterior Eye 41(5): 458-462.
3. Jaynes, J., et al. (2015). "Predicting scleral GP lens entrapped tear layer oxygen tensions." Cont Lens Anterior Eye 38(5): 392.
4. Severinsky, B., et al. (2014). "Scleral contact lenses for visual rehabilitation after penetrating keratoplasty: long term outcomes." Cont Lens Anterior Eye 37(3): 196-202.
5. Spierer, O. and M. Lazar (2014). "Urrets-Zavalia syndrome (fixed and dilated pupil following penetrating keratoplasty for keratoconus) and its variants." Surv Ophthalmol 59(3): 304-310.
6. Walker, M. K., et al. (2016). "Complications and fitting challenges associated with scleral contact lenses: A review." Cont Lens Anterior Eye 39(2): 88-96.