Marshall B. KETCHUM UNIVERSITY
Southern California College of Optometry

EBMD vs. Limbal Stem Cell Deficiency and Scleral Lens Wear

Valerie A Lim OD, Tim Edrington OD, MS, FAAO

BACKGROUND

An asymptomatic patient with a history of dry eye syndrome, scleral lens (ScL) wear, and long-term glaucoma medication use presented with presumed bilateral asymmetric limbal stem cell deficiency (LSCD). Limbal stem cells are critical to preserve healthy corneal epithelium and to serve as a barrier to prevent corneal conjunctivalization. LSCD occurs when these cells are damaged or disrupted and can be caused by many etiologies including contact lens (CL) wear. After further assessment and refitting into a corneal gas permeable lens, it was determined this patient had epithelial basement membrane dystrophy (EBMD).

CASE DESCRIPTION

VT, 71 y/o female, presented for 6-month ScL follow-up and anterior segment check

- **POHx:**
  - Keratoconus (KCN) OU
  - Dry eye syndrome OU, treated with Restasis BID OU
  - Primary open angle glaucoma (POAG) with latanoprost QHS OU
  - Age related macular degeneration (AMD) with AREDS2 BID po
  - s/p cataract extraction OD in 2018
- **CL history:**
  - Past history of corneal GP from age 15 to 50 with discontinuation due to dryness
  - Initial ScL fitting in 2019 to address KCN and dry eyes

PERTINENT FINDINGS

Presenting VA with ScL:
OD 20/30, stable to previous best corrected VA (BCVA)
OS 20/40, PH 20/30-, reduced compared to previous BCVA

ScL assessment OU:
0.5:1 central clearance, adequate limbal clearance in vertical meridian, trace limbal clearance in horizontal meridian, well aligned with sclera 360 degrees

Corneal findings:
Positive and negative staining of superior cornea extending into superior visual axis OS>OD with trace underlying haze OS, (+)Fleischer's ring OU, (-)Vogt's striae OU, (-)scarring OU

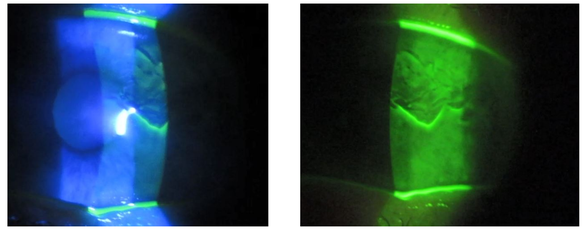

Figure 1. OS corneal findings post scleral lens removal

DIFFERENTIAL DIAGNOSES

- **Limbal stem cell deficiency (LSCD), possibly secondary to:**
  - Contact lens wear
  - Preservatives in topical ocular medications
  - Dry eye syndrome
- **Epithelial basement membrane dystrophy (EBMD)**

TREATMENT AND MANAGEMENT

Due to fluorescein pattern with underlying haze OS, initially diagnosed with presumed asymmetric LSCD OS>OD. Instructed patient to discontinue ScL wear OU.

After 1 week of no ScL wear, improvement seen in underlying haze OS. Initiated refitting into corneal rigid gas permeable lenses (RGPs) OU.

VA with finalized RGP lenses:
OD 20/30+2
- consistent with previous BCVA

OS 20/30+2
- improved compared to initial presentation with scleral, equivalent to baseline BCVA

Final RGP fit:
OU trace feathery apical touch, midperipheral pooling superiorly, average peripheral clearance 360 degrees, good movement with blink

Pt reported improvement in dryness symptoms with finalized RGPs compared to habitual ScL.

However, after further assessment during RGP refit, determined that patient was initially misdiagnosed with LSCD and that corneal findings were more indicative of EBMD.

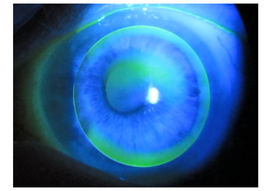

Figure 2. Corneal RGP fit OS

DISCUSSION

- Early to moderate stages of LSCD may present as punctate staining that can coalesce into linear configurations or confluent sheets. This presentation most commonly occurs at the superior limbus underneath the upper lid, especially with CL induced LSCD.[1]
- Soft CL wear has been indicated in LSCD presentations through various mechanisms including mechanical rubbing at the limbus by the superior eyelid, long term hypoxia, and toxic CL solutions. However, implications of corneal and ScL gas permeable lenses on affecting limbal stem cells are not widely understood.[1]
- Dry eye syndrome and preservatives in topical ocular medications can also contribute to LSCD manifestation.[1]
- VT heavily relies on CLs due to reduced BCVA in her spectacles 2' KCN. Her current dry eye regimen already includes ATs 4x/day and Restasis BID OU. Use of topical steroids may be contraindicated as she is currently on IOP management for POAG.
- Epithelial basement membrane dystrophy (EBMD) is the most common corneal dystrophy, affecting about 42% of the population[2], and can be described as diffuse grey patches, white cysts, or fine refractile lines within the corneal epithelium.
- Both LSCD and EBMD can have similar symptomatology (foreign body sensation or decreased vision) and clinical appearance. However, distinctions can be made based on close fluorescein examination.
- The diagnosis of LSCD can be made if late fluorescein staining in a whorl-like pattern is noted. This late staining is secondary to the conjunctivalization of the cornea with conjunctival epithelial cells being more permeable to fluorescein than corneal epithelial cells.[1]
- EBMD may exhibit fluorescein patterns with positive and negative staining due to the irregularity of the epithelial surface; however, the whorl-like and late staining pattern would not be observed with EBMD.[3]

CONCLUSIONS

- Scleral lenses have therapeutic indications in both LSCD and recurrent corneal erosions (RCEs) secondary to EBMD. Traditional corneal rigid gas permeable lenses can serve as an additional lens option for irregular cornea patients without negatively affecting corneal integrity.
- Conservative medical treatment for LSCD primarily includes cessation of CL wear, artificial tears (ATs), cyclosporine, and topical steroids.[1] Similar to LSCD, RCEs secondary to EBMD can also be conservatively treated with topical gels or ointments and therapeutic contact lenses.[4]
- Surgical options are available for severe cases of LSCD when medical therapies are ineffective. For cases of EBMD with associated RCEs where conventional therapy is unsuccessful, phototherapeutic keratectomy (PTK) can be utilized.[4]
- Due to the rarity of LSCD and high prevalence of EBMD, improvement in symptoms with corneal RGPs, negative history of soft CL wear, and corneal fluorescein pattern, patient determined to have EBMD rather than LSCD.
- Discussed with patient, VT, that both corneal and scleral lenses may be worn with EBMD condition since patient does not have prior history of RCEs. Informed patient that corneal RGP may result in healthier corneal surface with increased tear exchange and oxygen permeability. Patient was also educated on association of EBMD with RCEs.

REFERENCES

1. Rossen, J., Amram, A., Milani, B., Park, D., Harthan, J., Joslin, C., Djalilian, A. (2016). Contact Lens-induced Limbal Stem Cell Deficiency. The ocular surface, 14(4), 419–434. doi:10.1016/j.jtos.2016.06.003
2. Werblin, T. P., Hirst, L. W., Stark, W. J., & Maumenee, I. H. (1981). Prevalence of map-dot-fingerprint changes in the cornea. The British journal of ophthalmology, 65(6), 401–409. doi:10.1136/bjo.65.6.401
3. Vemuganti G.K., Rathi V.M., Murthy S.I. Histological landmarks in corneal dystrophy: Pathology of corneal dystrophies. Dev. Ophthalmol. 2011;48:24–50. doi: 10.1159/000324261
4. Lisch W, Seitz B (eds): Corneal Dystrophies. Dev Ophthalmol. Basel, Karger, 2011, vol 48, pp 116–153. doi: 10.1159/000324081