Marshall B. KETCHUM UNIVERSITY
Southern California College of Optometry

Cosmetic Contact Lens for Band Keratopathy

Reid Gardner, OD

INTRODUCTION

Band keratopathy (BK) is an interpalpebral, whitish opacity of calcium deposits at the level of Bowman's membrane. It typically originates in the peripheral cornea with a small gap between it and the limbus. Holes are often present in the plaque where nerves are coursing anteriorly, and thick portions can flake off resulting in a painful epithelial defect.

Patients often present with reduced visual acuity, irritation, pain, photophobia, and a concern over the cosmetic appearance of the eye.

CASE PRESENTATION

A 73-year-old white male was referred for cosmetic improvement of his left eye which had BK. The patient reported that he did not want to have a "zombie eye" as his grandson had described it. The patient had never worn contact lenses and desired to wear a cosmetic contact lens when out in public only.

The patient's ocular history included PDR OD, DME OD, Vitreous heme OD, PCIOL OD, CRAO OS, funnel RD OS, and BK OS. His entering acuities were 20/25^{-2} OD and NLP OS. Slit lamp examination of the left cornea exhibited BK nasally about 4mm in size with overlying mild SPK, trace diffuse haze throughout the cornea, and moderate peripheral neovascularization superiorly and inferiorly. The anterior chamber space was primarily occupied with a white lenticular or fibrous material that was in contact with the posterior cornea.

DISCUSSION

At the initial visit, the patient was fit in an Air Optix Colors (Brown color / Plano sph / 8.6 BC / 14.2 DIA) on the left eye. The fit was mildly loose but was otherwise centered and comfortable. The improvement of cosmesis was incomplete as the white opacification was visible through the center of the contact lens. The patient's left spectacle lens was also fogged with a translucent tape as an alternative cosmetic option. Both the colored contact lens trial and fogged spectacle were dispensed along with instructions for the patient to trial both options to decide if contact lens wear, insertion, and removal was manageable and if either option would fit into the patient's lifestyle. If feedback was positive, a custom soft cosmetic lens would be pursued.

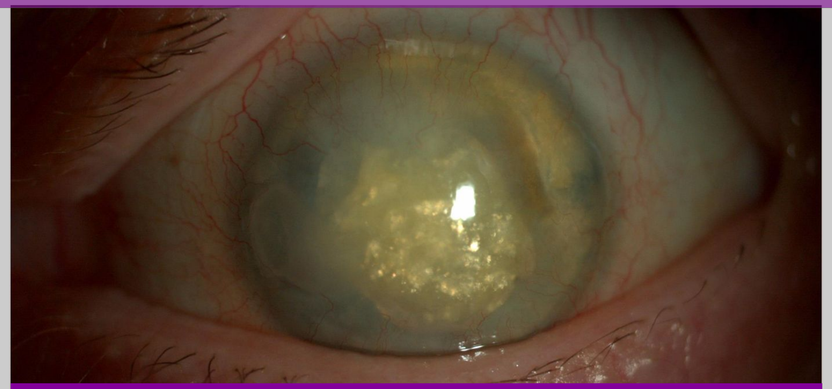

Figure 1 White appearance of nasal BK & central anterior chamber opacity.

Figure 2 Cosmetic appearance of opacities of left eye.



Figure 3 Orion BioColors contact lens ordered.

Figure 4 Cosmetic appearance after contact lens insertion.

At the follow-up visit, the patient reported that contact lens wear was viable and that the fogged spectacle was also helpful for certain situations. The patient desired moving forward with fitting a customized soft contact lens.

The patient was fit with the Orion BioColors contact lens with similar parameters as the Air Optix Colors including 8.6 BC / 14.2 DIA / U1 underprint / Pecan #55 iris color / 2.5mm black pupil / 12.25mm iris diameter. Cosmesis was significantly improved, and the patient was pleased with the outcome.

CONCLUSION

Cosmetic contact lenses play an important role in the improvement of cosmesis of BK and other opacified or otherwise distorted ocular appearances, but other stepwise alternatives are available so as to save time and money. In this particular case, a generic mass-produced colored contact lens was dispensed to quickly and easily confirm that the patient would indeed be interested in a contact lens even when considering the required maintenance and skill required. Poor vision and dexterity could have been barriers that made insertion and removal difficult. Fogged spectacles are also an easy alternative that may provide adequate improved cosmesis depending on patient preference.

REFERENCES

Stokkermans, T. J. (2017, January 15). A Hands-on Approach to Band Keratopathy. Retrieved from www.reviewofoptometry.com/article/a-handson-approach-to-band-keratopathy.

Donaghy, C. L., Vislisel, J. M., Greiner, M. A., Goins, K. M., & Wagoner,, M. D. (2015, June 2). Retrieved from https://webeye.ophth.uiowa.edu/eyeforum/cases/214-band-keratopathy.htm.

Jhanji, V., Rapuano, C. J., & Vajpayee, R. B. (2011, July). Corneal calcific band keratopathy. Retrieved from https://www.ncbi.nlm.nih.gov/pubmed/21537183.