Let's Clear Things Up: Improving Visual Acuity in Case of Post- LASIK Ectasia

Ryan Yee, Nicholas Gidosh, OD, FAAO
Pennsylvania College of Optometry

INTRODUCTION

Gas permeable (GP) contact lenses can deliver high-quality optics all the while providing high oxygen transmissibility. The rigidity nature of corneal GPs can improve the visual performance of patients with corneal ectasias such as those with keratoconus, pellucid marginal degeneration, and post-LASIK ectasia.

HISTORY

Patient is a 43-year-old Hispanic female with a history of LASIK refractive surgery in the 1990s. She reports blurry vision at both distance and near and previously tried GPs many years ago. Prior to our visit, she underwent corneal cross linking to help stabilize her corneal ectasia. Systemic history is unremarkable, and she was not taking any medications at the time of our visit.

CLINICAL FINDINGS

	OD	OS
Visual Acuity (uncorrected)	20/30	20/40
SLE	Mild ectasia inferiorly, mild deep stromal haze. (-) Vogt's striae or apical scarring	Mild ectasia inferiorly, mild deep stromal haze. (-) Vogt's striae or apical scarring

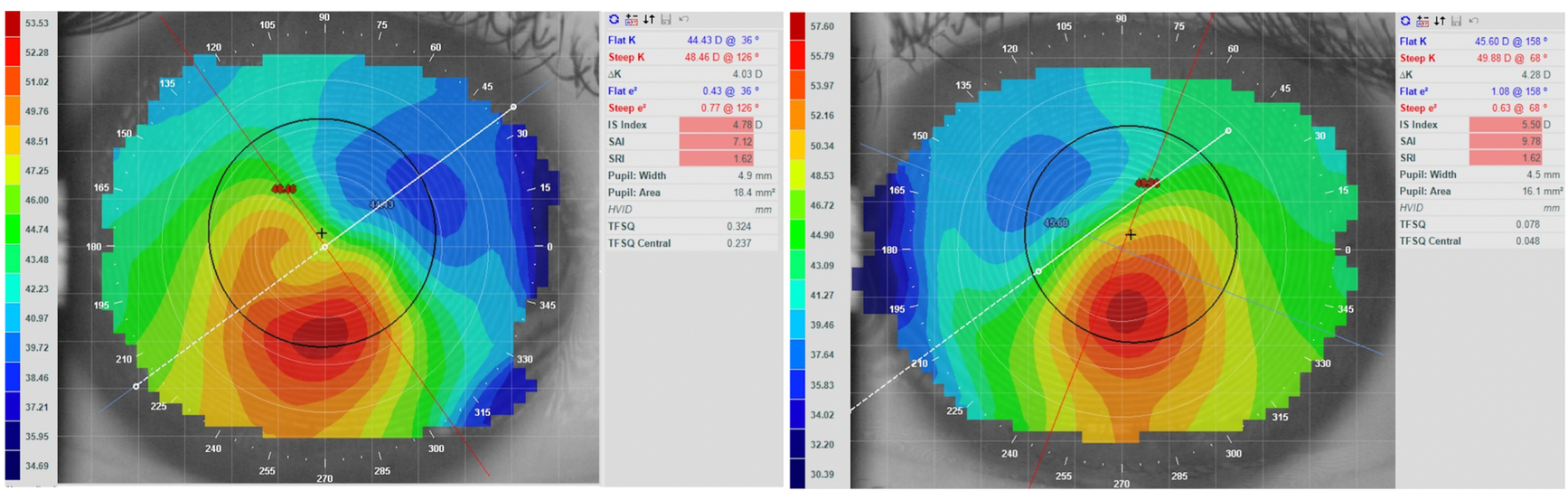

FIGURE 1: Topography of OD (right) and OS (left) reveals ectasia with steepening inferiorly which is the cause of the patient's reduced vision.

TREATMENT AND MANAGEMENT

After discussing the different modalities, we decided to refit the patient in a corneal gas permeable. The Rose K2 IC lens was chosen due to its large diameter that helps with centration and that minimizes movement to improve comfort. These lenses also offer an aspheric back surface and large optic zones, both of which can improve visual outcomes.

	Lens	Base Curve/ Diameter	Power	Peripheral Curve	Center Thickness	Material
OD	Art Optical K2 IC	7.34/10.70	-1.75D	Standard	0.18mm	Optimum Comfort
OS	Art Optical K2 IC	7.40/10.70	-1.25D	Standard	0.18mm	Optimum Comfort

Dispense:
Patient was able to achieve 20/20 vision OD, OS and OU with the lenses. Light feathery touch centrally and good tear flush. Diameter of the lens was large and well centered. Dispensed lenses to patient and patient was educated to slowly build up wear time.



FIGURE 2: Slit lamp examination OD (right) and OS (left) with fluorescein dye demonstrates light feathery touch centrally with good tear flush and centration.

Follow- up (2-week):
Patient reported excellent vision and comfort with up to 12 hour of wear time at the 2-week follow-up. Slit lamp examination showed good fluorescein pattern with light feathery touch centrally and good tear flush.

Follow- up (1-month):
Patient reports being able to wear her corneal GPs for up to 12 hours with no issues with comfort, whilst providing the patient with excellent vision.

DISCUSSION AND CONCLUSION

Corneal ectasia is a rare but visually debilitating condition that can occur following LASIK and PRK. Cases of ectasia can occur immediately after LASIK or after a few years. Proper screening and patient selection is crucial in reducing these incidences. In cases of corneal irregularities, specialty contact lenses can reduce the need for surgically invasive procedure whilst providing functional vision.

The Rose K2 IC lenses are great choices for post-LASIK ectasia due to its large diameter, which can minimize discomfort and due to its aspheric back design, which can provide outstanding optics. Among the different modalities of lenses available to mask irregularities, corneal GP lenses are excellent options for providing exceptional vision and for allowing high amounts of oxygen to reach the cornea.

REFERENCES

Available upon request