Marshall B. KETCHUM UNIVERSITY
Southern California College of Optometry

Prosthetic Device and Specialty Contact Lens Prescribing for Ocular Trauma: A Case Series

Annie Lee, OD Dawn Lam, MSc, OD, FAAO Timothy Edrington, OD, MS, FAAO

INTRODUCTION

According to the U.S. Eye Injury Registry, approximately 2.4 million eye injuries occur annually. Although ophthalmologists play a critical role in surgical treatment of patients with acute ocular trauma, optometrists play an integral role in managing the cosmesis and ocular health of these eyes post- surgery. This case series reviews different approaches to prescribing specialty contact lenses (a soft prosthetic contact lens, a clear scleral GP lens, and a prosthetic scleral shell) to manage three patients with a history of ocular trauma.

CLINICAL PEARLS

Specialty contact lenses and prosthetic devices can provide the most suitable option for patients with a history of ocular trauma. Eye care practitioners play an integral role in the management of these patients. Some important considerations include assessing functional vision and supporting ocular tissue. These factors guided and influenced our final treatment and management for these patients.

REFERENCES

1. Lam D. Soft Contact Lenses for Prosthetic Fitting. *Contact Lens Spectrum*. 2015; 30(3): 33-9.

2. Chiu G, Theophanous C, and Irvine J. PROSE Treatment in Atypical Ocular Graft-Versus-Host Disease. *Optometry and Vision Science*. 2016; 93(11): 1444-8.

3. Pine KR, Sloan BH, and Jacobs RJ. Scleral Shell Prostheses and Prosthetic Contact Lenses. In: *Clinical Ocular Prosthetics*. Switzerland: Springer International Publishing; 2015: 160-2.

CASE #1: 66 year old Caucasian male

CASE HISTORY

- Chief complaint: glare and halos secondary to traumatic iris injury OD (age 4)
- Ocular history: ocular trauma OD, traumatic cataract OD
  - History of hand-painted prosthetic soft contact lens
- Medical history: systemic hypertension, hypercholesterolemia, chronic myelogenous leukemia

PERTINENT CLINICAL FINDINGS

	OD	OS
BCVA	CF at 1 ft	$20/20^{-2}$
Cornea	Linear, white opacification (inferior temporal) secondary to longstanding healed laceration	Clear
Iris	Iris atrophy and irregular pupil opening	Blue and flat

TREATMENT AND MANAGEMENT

- Printed prosthetic soft contact lens OD
  - Orion Biocolors
  - Underprint: U3-Stormy
  - Iris: 52-Granite Gray-V
  - Power: plano DS

Fig 1A. Printed prosthetic soft contact lenses. Multiple lenses are layered during the fitting process to achieve the desired effect.

DISCUSSION

A prosthetic soft contact lens can provide iris occlusion and improve symptoms of glare and photophobia after traumatic iris injury. Iris occlusion lenses are best prescribed with a black opaque iris backing to minimize symptoms of glare.[1] The size options for pupil openings may be limited, so consultation with your lab is recommended when managing these patients.

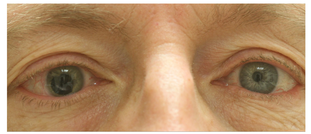

Fig 1B. Pupil asymmetry is observed between OD and OS. Irregular pupil opening OD is the cause of glare.

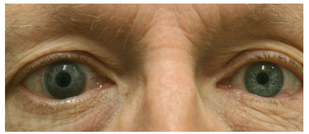

Fig 1C. Improved symmetry and cosmesis between OD and OS. The right eye is wearing a printed prosthetic soft contact lens. The smaller pupil opening reduces glare.

CASE #2: 71 year old Caucasian male

CASE HISTORY

- Chief complaint: ocular surface discomfort and blurred vision OU
- Ocular history: chemical (alkali) burn, traumatic glaucoma, limbal stem cell deficiency OU
  - Surgery: all performed between 2015 and 2017
    - OD: corneoscleral graft, tube shunt surgery
    - OS: limbal stem cell transplant x 2, penetrating keratoplasty x 2, tube shunt surgery, cataract extraction, tarsorraphy
- Medical history: type II diabetes mellitus, elevated cholesterol, hypertension

PERTINENT CLINICAL FINDINGS

	OD	OS
Manifest Refraction VA	20/100	CF at 2 ft
Cornea	Diffuse corneal clouding and irregularity, 2 mm neovascularization 360, central persistent epithelial defects	
Conjunctiva	Exposed sutures, irregular vascularization	
Keratometry	42.18 / 50.16 @ 104	Unable to assess due to irregularity
Iris	Surgical corectopia	Fixed, dilated

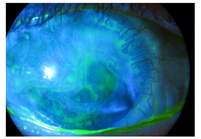

Fig 2A. The patient's right eye. The ocular surface shows signs of limbal stem cell failure and corneal neovascularization.

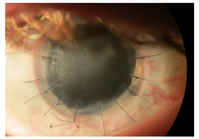

Fig 2B. The patient's left eye. The left eye has had multiple penetrating keratoplasties and limbal stem cell transplants resulting in an irregular cornea and conjunctiva.

TREATMENT AND MANAGEMENT

- Jupiter Scleral GP lens OU
  - OD: 16.6 REV / 45.00 D / plano DS VA: 20/100+1 PH: NI
  - OS: 16.6 REV / 26.00 D / +21.00 D VA: 20/125 PH: NI

Fig 2C. Finalized scleral lenses for the left and right eye. The shallow sagittal height of the left lens matches the flat curvature of the ocular surface.

DISCUSSION

Patients with a history of severe chemical injury to the eye can suffer from limbal stem cell deficiency, irregular corneas, and persistent epithelial defects. These corneas heal slowly and often require specialty contact lenses to rehabilitate the ocular surface. Scleral GP lenses provide an option for ocular surface protection and can improve patients' quality of vision.[2]

CASE #3: 64 year old African American male

CASE HISTORY

- Chief complaint: eyelid asymmetry, OD smaller than OS
- Ocular history: knife injury OD (age 8)
  - History of prosthetic scleral shell, discontinued prosthetic shell 20 years ago

PERTINENT CLINICAL FINDINGS

	OD	OS
BCVA	No light perception	20/15 (-3.75 DS)
Globe	Phthisis bulbi	Unremarkable
Palpebral Aperture Height	8 mm	10 mm
Cornea	Complete corneal opacification	Unremarkable

TREATMENT AND MANAGEMENT

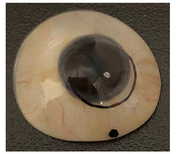

Fig 3A & 3B. The process of repositioning the iris location and pupil diameter.

Fig 3C. A scleral shell compared to the patient's seeing eye for color matching purposes.

DISCUSSION

A prosthetic scleral shell can equalize eyelid symmetry in patients who have lost visual function and who have ocular tissue atrophy. They are indicated in cases where the palpebral aperture is smaller than that of the functional eye and when the non-functional eye is phthisical or strabismic.[3]

Fig 3D. Cosmetic asymmetry between the right eye and the left eye.

Fig 3E. Improved symmetry and cosmesis between the right eye and the left eye.