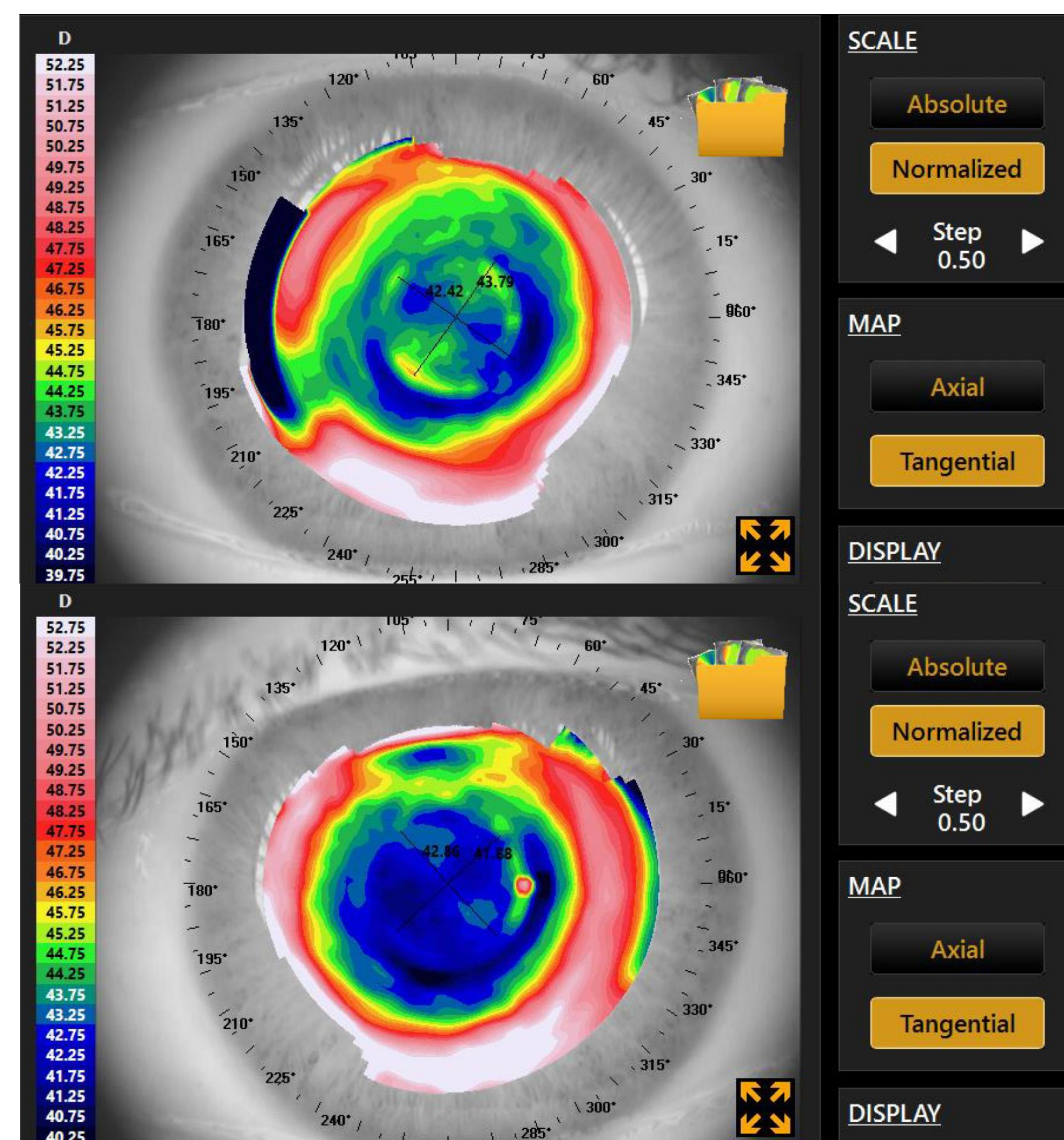


Introduction

As refractive surgical technology continues to improve, more and more patients are electing to have it for management of ametropia. LASIK for myopia continues to be the most common procedure performed. It works by creating a flap and ablating central corneal stromal tissue to thereby flatten a central treatment zone. This gives the post surgical cornea an oblate shape with negative eccentricity because the peripheral cornea has been relatively steepened.¹

Although the LASIK procedure and its outcomes have improved over the past two decades it still has its limitations and complications that result from the surgery including glare, starbursts, ghosting monocular diplopia, reduced contrast, and other symptoms. These are a result of higher-order aberrations, most commonly experienced in low light conditions, which can be caused by decentered ablations, ablation asymmetry, flap striae, and small treatment diameter.² The patient in this case showed appropriately sized and well centered treatment zones (Figures 1 and 2).

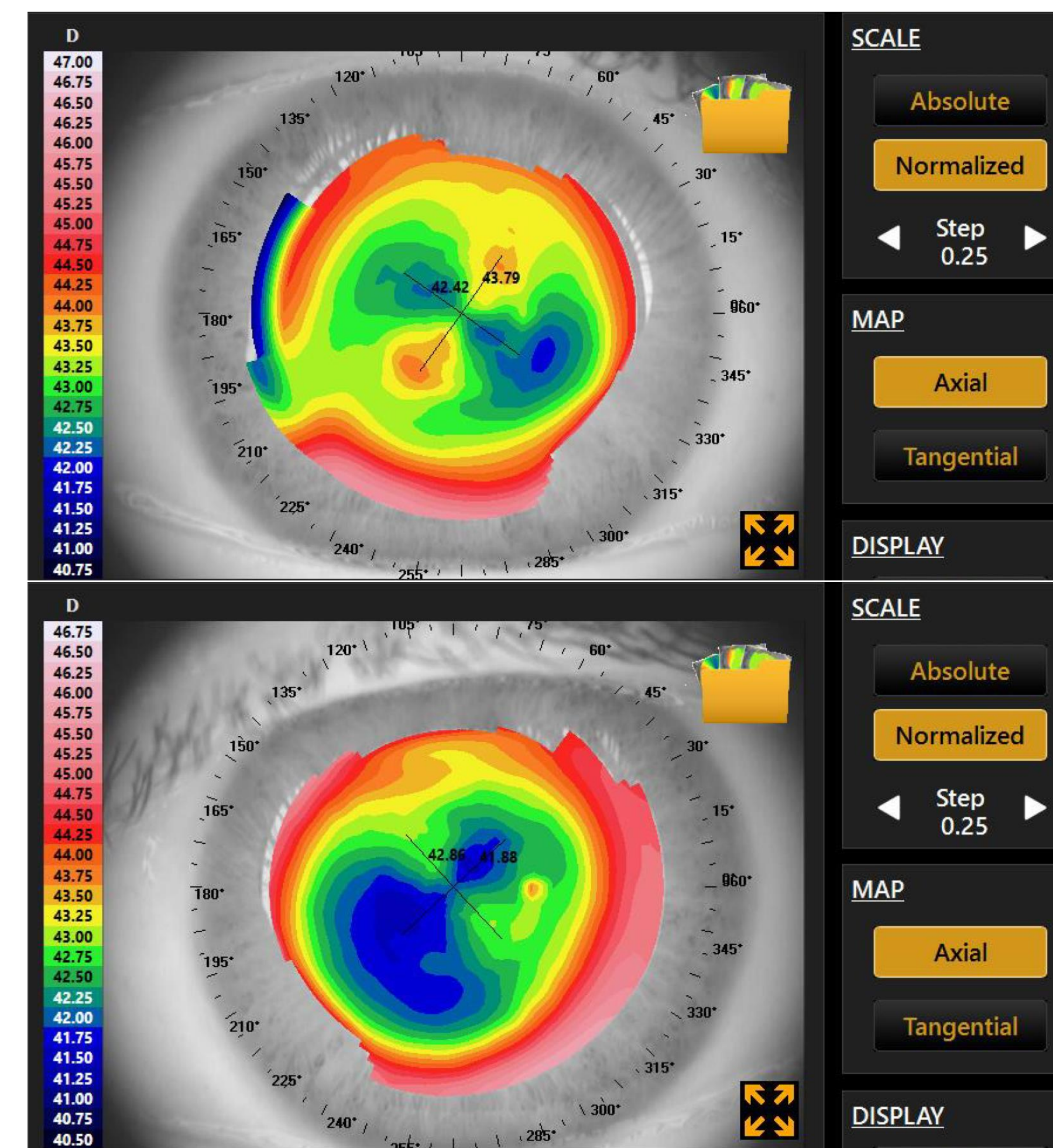


Figures 1 and 2 show tangential maps OD top and OS bottom. These show good centration of treatment zones with some corneal astigmatism remaining OD.

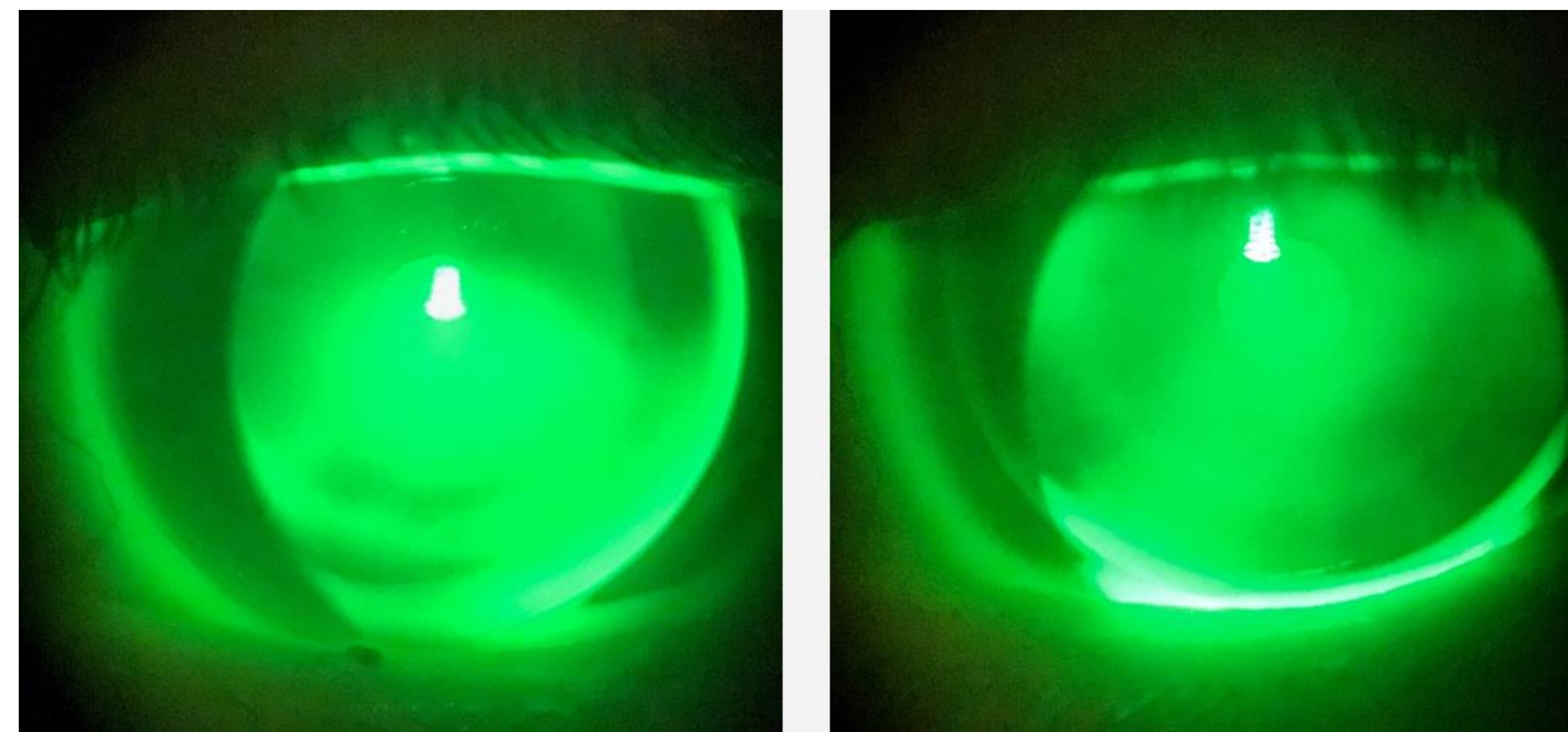
Gas-permeable (GP) contact lenses fit after LASIK offer not only correction of residual of ametropia but also a therapeutic effect of resolving symptoms that result from higher-order aberrations. This is because of a symmetrical back optic zone radius and the tear lens between there and the cornea.³ The ametropia may be a result of over/under correction or lenticular changes after several years.^{4,5} GPs are excellent for these patients because of oxygen transmissibility, tear pumping under the lens, and a tear lens to neutralize irregular astigmatism.⁴ GPs are also more customizable to allow reverse-geometry design, which can provide better centration on these oblate surfaces and improve lens-cornea interface reducing coma. Aspheric design can also be used to reduce spherical aberration.² The flap's physical integrity is such that a GP lens can safely be fitted after two to three months, once refractive error has stabilized, if a patient's visual demands are such; however, it is often recommended to delay contact lens fitting until six months after LASIK. It is also recommended that these patients be fit diagnostically; however there are fitting guide recommendations for some empirical designs.⁴

Case Presentation and Results

- A 49 year old female presented for contact lens fitting as a new patient with history of LASIK in each eye
- She reported increased difficulty at near and wanted to avoid having to use reading glasses as often
- Best corrected VA at distance was:
 - 20/15⁻² OD with – 0.75 – 0.50 x 150
 - 20/15⁻² OS with – 0.75 sphere
- She corrected to 20/20 at near with +2.00 add
- Pupils were 3.75 mm OD and OS under mesopic conditions
- Slit lamp examination revealed LASIK scars OU with an old re-epithelialized scar near the flap OD
- HVID was 11.6 mm OD and OS measured by topographer
- Topography was taken with Topcon CA800 computerized corneal topographer (Figures 1, 2, 3, and 4).
- Axial maps (Figures 3 and 4) were used to design reverse-geometry multifocal GP lenses to meet the patients visual needs



Figures 3 and 4 show axial maps OD top and OS bottom. Sim K values for the flat meridian were used in calculating the power of the empirically designed lenses.



Figures 5 (OD on left) and 6 (OS on right) above show fluorescein patterns of the empirical lenses applied to each eye. No harsh areas of bearing were seen.

- Empirical lenses were assessed on eye, showing pooling over flattened central areas (Figures 5 OD and 6 OS) with good movement and centration. Over-refraction was plano OD and OS.
- Patient was happy with functional vision provided by the lenses: 20/20⁺² OD, OS, and OU at distance and 20/30 at near

Results Continued and Discussion

- The patient was fit with reverse-geometry GP lenses with the following parameters:

	OAD	BC	OZD	BVP	Add	Near Zone	Reverse Curve
OD	10.8	7.94	7.0	-1.00	+2.00	2 mm	7.71/1.4 mm
OS	10.8	7.96	7.0	-1.25	+2.00	2 mm	7.75/1.4 mm

In this case the CLASIKcn lenses were empirically designed based on topography and fitting guide recommendations. The “average blue” was selected from the axial map to be around 42.50D for the right eye, slightly steeper than flat K, so the power was adjusted – 0.25 D for the tear lens. A base curve was selected similarly OS with the same type of power modification. The reverse curve in this design is selected by fitting one diopter flatter than “average red” outside the treatment zone.⁶ In this case, the least amount of reverse-geometry was used in the design. This was a because the patient had only had about two diopters of myopia prior to treatment so was not flattened as much centrally.

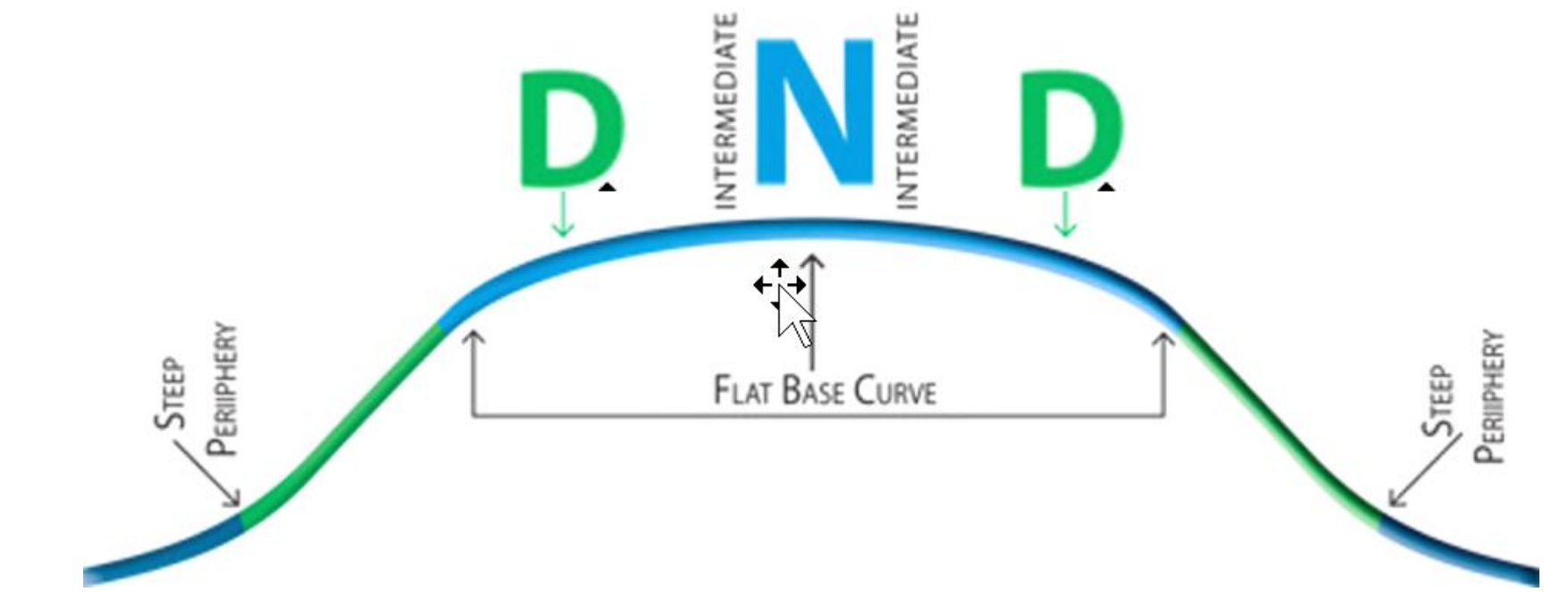


Figure 7 shows CLASIKcn design with front surface center near optics (2 mm zone in this case) with intermediate and distance zones outside to provide simultaneous multifocal optics

Designs can also made using pre-surgical data; however, not much information was available in this case. The fluorescein patterns in Figures 5 and 6 are appropriate for the design and correspond with the flat areas of the axial maps, particularly OS. If there is too much pooling centrally from excessive sagittal differences (not enough reverse-geometry) vision can be unstable upon blinking, particularly problematic in a multifocal.⁷ Good centration was critical in this case because of the center near optics, and the movement ensured there was a sufficient tear pump. The reverse curve is what is adjusted to change the fit as it controls the sagittal height of the lens to align with the mid-peripheral cornea. If the fit must be adjusted it is generally not recommended to adjust the base and reverse curves simultaneously.⁵

Conclusion

Reverse-geometry corneal lenses offer healthy design options that center well on patients who have elected LASIK. This centration can be used to deliver multifocal optics once those patients reach presbyopia. Patients should have reasonable expectations for resultant functional vision. Corneal topography serves as a useful tool in being able to design lenses empirically for some of these patients.

References

- Frogozo M. Fitting rigid lenses after refractive surgery. *Review of Cornea & Contact Lenses*. 2016. Jun;16:20.
- Gemoules G, Morris KM. Rigid gas-permeable contact lenses and severe higher-order aberrations in postsurgical corneas. *Eye and Contact Lens*. 2007. 33(6): 304-307.
- Gemoules G. Therapeutic effects of contact lenses after refractive surgery. *Eye and Contact Lens*. 2005. 31(1): 12-22.
- Zadnik K. Contact lens management of patients who have had unsuccessful refractive surgery. *Curr Opin Ophthalmol*. 1999 Aug; Vol. 10 (4): 260-263.
- Ensley R, Miller H. Refractive surgery fall out: GPs to the rescue. *Review of Cornea & Contact Lenses*. 2017. Mar/Apr;38-39.
- Art Optical. CLASIKcn fitting guide. https://www.artoptical.com/storage/docs/CLASIKcn_SS_15.pdf
- Gonzalez-Mejome JM et al. Correlations between central and peripheral changes in anterior corneal topography after myopic LASIK and their implications in postsurgical contact lens fitting. *Eye and Contact Lens*. 2006. 32(4): 197-202.