Utilization of OCT Imaging to Improve Office Efficiency in an Atypical Scleral Lens Fit

Author: Ryan McKinnis, OD, FAAO, FSLS

Background:

- 46 year old male suffers from multiple foreign bodies following a black powder explosion at his home.
- Attempted corneal RGPs at another practice but disliked comfort.
- Complains of excessive glare and halos at all times that worsen during nighttime activities.
- Patient claims that his spectacle Rx was nearly equal between each eye prior to the accident
- Works as maintenance at a local steel mill – it is an exceptionally dirty environment.

Case Report:

Spectacle Rx

OD: -1.25 -3.75 x 030 20/30 (with ghosting)
OS: -1.00 -0.50 x 100 20/20- (with ghosting)

Keratometry

OD: 43.50/45.37
OS: 43.50/44.00

Pupil Size

3.00 mm

Corneal Diameter

11.75 mm

Photos Of Corneal Foreign Bodies

Image 1 Corneal foreign bodies

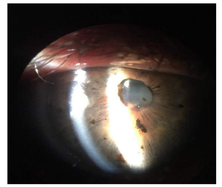

Image 2 Corneal foreign bodies

Corneal Topography

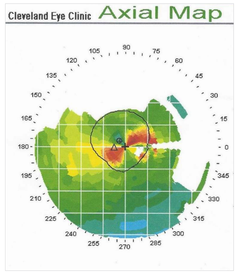

Figure 1 Corneal Topography

Scleral Lens Fitting:

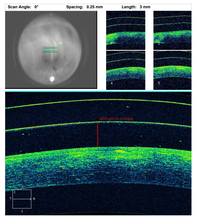

Figure 2
Initial trial lens 3600/8.40/16.0 PCs: 36/42
Image shows excessive central clearance with OCT imaging

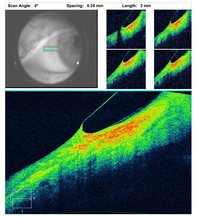

Figure 3
OCT imaging shows a tight fit in the periphery
Flat axis of lens located at 160 degrees
Over-Refraction: +1.75 -1.50 x 020

Lens Ordered:

400/8.40/16.0

PCs: 34/40

Rx: +1.75 -1.50 x 040

Menicon-Z material

Follow Up:

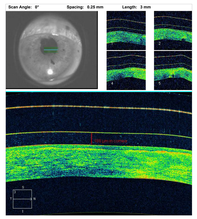

Figure 4
Lens shows more appropriate central clearance via OCT imaging

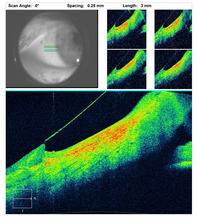

Figure 5
Lens shows more appropriate peripheral fitting relationship via OCT imaging
BCVA: 20/20

Conclusion:

The patient is able to wear the lenses during all waking hours. Glare, halos, and ghosting have decreased by approximately 90%. Some residual halos are still present at nighttime but per the patient these are manageable. The fitting relationship has remained stable and consistent over the past twelve months.

The patient reports needing to "squeegee" his lenses to clean the anterior surface once per day while at work. He does not need to do this while at home.

The SynergEyes VS lens behaves in a predictable manner which allows for the use of OCT technology to limit the number of trial lenses utilized; thus, chair time is reduced and office efficiency improves.

Since adopting OCT technology as the primary means of managing scleral lens fits chair time has been reduced by nearly 50% while remakes associated with a poor fit have decreased by 20%.